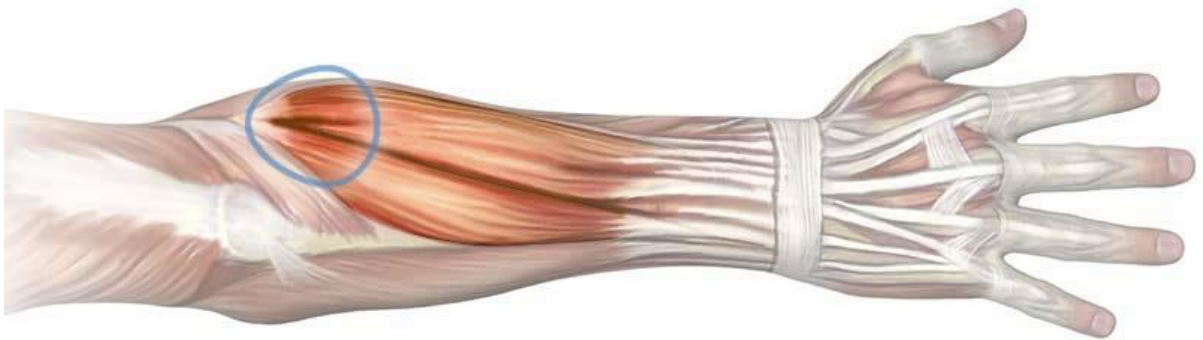


Elbow, Wrist and Hand

Anatomy, movements, dysfunctions, manipulations



Compiled by Laurence Hattersley
7-8-2014

Contents

Elbow, Wrist and Hand	1
Joints of the Elbow	1
Joints and ligaments of the elbow	2
Muscles moving the elbow	3
Bones of the forearm	6
Muscles of the forearm	7
Nerves supplying the arm	10
Anterior groups of muscles – Nerves and root values	10
Posterior groups of muscles – nerves and root values	11
Injuries to Elbow	12
Fractures	12
Olecranon fractures	12
Supracondylar fractures	12
Avulsion fractures	13
Dislocations	13
Radial head dislocation	14
Distal Biceps Tendon Rupture	16
Rupture of Distal end Triceps	16
Repetitive Strain injuries at Elbow	16
Common Extensor Origin	17
Common Flexor Origin	19
Wrist drop	19
Ulnar Nerve Entrapment at the Elbow	21
Osteochondritis Dissecans	23
Panner’s Disease	24
Osteoarthritis	24
Manipulations of the Elbow	1
Wrist and Hand	3
The Wrist	3
Flexor Retinaculum and Carpal Tunnel	4
The Extensor Retinaculum	6
The Anatomical Snuffbox	6
Movements of the wrist	7
The Hand	8
Bones	8
Joints	8
Muscles of the Hand – Intrinsic Muscles	9
Injuries to the Wrist	12
Fractures – Distal Radius	12
Colles’ Fracture	12
Salter-Harris fracture	12
Smith’s fracture	13
Barton’s Fracture	14
Chauffeur Fractures	14
Scaphoid fracture	15
Bennett’s fracture	16

Galeazzi fracture	16
Hamate fracture	16
Dislocated wrist	17
Kienböck Disease	17
Ulnar impaction syndrome	19
Triangular fibrocartilage complex	19
Carpal tunnel Syndrome	24
Tenosynovitis	27
De Quervain’s Disease	28
Rheumatoid Arthritis	29
Osteoarthritis	31
Boxer’s Fracture	32
Avulsion fractures	33
Mallet finger	33
Gamekeeper’s thumb	33
Dislocations	34
Nodules on Tendons – Trigger Finger	34
Dupuytren’s contracture	35
Manipulations and mobilisations of Wrist	36
Biscuit Breaking	36
Torsion	36
Figure of eight	36
Shearing of radio carpal	37
Shearing of intercarpal joint	37
Shearing of carpometacarpal joints	37
Manipulation of wrist joints	37

<i>Figure 1 Elbow from front</i>	<i>Figure 2 Elbow from medial side</i>	1
<i>Figure 3 supination and pronation of forearm</i>		1
<i>Figure 4 Elbow joint and ligaments</i>		2
<i>Figure 5 The carrying angle</i>		2
<i>Figure 6 Olecranon fossa</i>		3
<i>Figure 7 Biceps Brachii</i>		3
<i>Figure 8 Brachialis</i>		3
<i>Figure 9 Brachioradialis</i>		4
<i>Figure 10 Pronator Teres</i>		4
<i>Figure 11 Triceps</i>		5
<i>Figure 12 Supinator</i>		5
<i>Figure 13 Pronator quadratus</i>		6
<i>Figure 14 Bones of forearm</i>		6
<i>Figure 15 Flexor muscles of forearm</i>		7
<i>Figure 16 Flexor tendons in hand</i>		8
<i>Figure 17 The tendons in the fingers</i>		8
<i>Figure 18 Extensor muscles of forearm</i>		9
<i>Figure 19 Olecranon fracture</i>		12
<i>Figure 20 Supracondylar fracture</i>		12
<i>Figure 21 Avulsion fracture of medial epicondyle</i>		13
<i>Figure 22 Dislocation of humero-ulnar joint</i>		13
<i>Figure 23 Partial dislocation</i>		14
<i>Figure 24 Elbow joint line - Normal</i>		14
<i>Figure 25 Dislocated radial head - schematic</i>		14
<i>Figure 26 Dislocation of radial head - X-ray</i>		15
<i>Figure 27 Relocation of radial head</i>		15
<i>Figure 28 Ruptured distal tendon of biceps</i>		16
<i>Figure 29 Ruptured triceps tendon</i>		16
<i>Figure 30 the axilla</i>		19
<i>Figure 31 Posterior axilla showing triangular space</i>		20
<i>Figure 32 Sensory nerve distribution in hand</i>		21
<i>Figure 33 Ulnar nerve distribution</i>		21
<i>Figure 34 Ulnar nerve around the elbow</i>		22
<i>Figure 35 osteochondritis dissecans</i>		23
<i>Figure 36 Osteoarthritis of elbow</i>		24
<i>Figure 37 HVT radial head</i>		1
<i>Figure 38 HVT radial head - 2</i>		2
<i>Figure 39 Muscle energy technique to extensor group</i>		2
<i>Figure 40 Bones of wrist and hand</i>		3
<i>Figure 41 Wrist bones</i>		3
<i>Figure 42 Flexor retinaculum</i>		4
<i>Figure 43 Flexor retinaculum and contents</i>		5
<i>Figure 44 Median nerve distribution in hand</i>		5
<i>Figure 45 Ulnar nerve in Guyon's tunnel</i>		5
<i>Figure 46 Ulnar nerve distribution</i>		5
<i>Figure 47 Extensor retinaculum</i>		6
<i>Figure 48 Anatomical snuffbox</i>		6
<i>Figure 49 Tendons to fingers</i>		7
<i>Figure 50 Radial and ulnar deviation</i>		7
<i>Figure 51 Bones of hand</i>		8
<i>Figure 52 Finger ligaments</i>		9
<i>Figure 53 Thenar and hypothenar muscles</i>		9
<i>Figure 54 Dorsal interossei</i>		10

<i>Figure 55 Palmar interossei</i>	11
<i>Figure 56 Lumbricals</i>	11
<i>Figure 57 Colles' fracture X-ray</i>	12
<i>Figure 58 Salter-Harris fracture</i>	12
<i>Figure 59 Smith's fracture</i>	13
<i>Figure 60 Die Punch Fracture</i>	13
<i>Figure 61 Barton Fracture</i>	14
<i>Figure 62 Chauffeur Fracture</i>	14
<i>Figure 63 Scaphoid fracture</i>	15
<i>Figure 64 Bennett's fracture</i>	16
<i>Figure 65 Galeazzi Fracture</i>	16
<i>Figure 66 Hamate fracture</i>	16
<i>Figure 67 Dislocated wrist</i>	17
<i>Figure 68 Dislocation of lunate bone</i>	17
<i>Figure 69 Kienböck disease</i>	18
<i>Figure 70 TFCC A-P view</i>	19
<i>Figure 71 Triangular Fibrocartilage Complex - Axial view</i>	19
<i>Figure 72 Distal ends of radius and ulna: joints and ligaments</i>	20
<i>Figure 73 TFCC and Meniscus</i>	21
<i>Figure 74 Traction Injury to TFCC</i>	21
<i>Figure 75 Carpal tunnel syndrome</i>	24
<i>Figure 76 Tinel's test</i>	25
<i>Figure 77 Phalen's test</i>	26
<i>Figure 78 Median nerve course into arm</i>	26
<i>Figure 79 Location of De Quervain's disease</i>	28
<i>Figure 80 Finkelstein test</i>	28
<i>Figure 81 De Quervain's anatomy and treatment</i>	29
<i>Figure 82 Rheumatoid arthritis – stages</i>	29
<i>Figure 83 Swan neck deformity of fingers</i>	30
<i>Figure 84 Osteoarthritis of the hands</i>	31
<i>Figure 85 Boxer's fracture</i>	32
<i>Figure 86 Fracture healing times of fingers</i>	32
<i>Figure 87 Mallet finger</i>	33
<i>Figure 88 Gamekeeper's thumb</i>	33
<i>Figure 89 Finger dislocation</i>	34
<i>Figure 90 Finger dislocation splint</i>	34
<i>Figure 91 Trigger finger</i>	34
<i>Figure 92 Dupuytren's contracture</i>	35
<i>Figure 93 Biscuit breaking</i>	36
<i>Figure 94 Torsion</i>	36
<i>Figure 95 Figure of 8</i>	36
<i>Figure 96 Shearing radiocarpal</i>	37
<i>Figure 97 Shearing intercarpals</i>	37
<i>Figure 98 Shearing carpometacarpal joints</i>	37
<i>Figure 99 manipulation of wrist</i>	37

Elbow, Wrist and Hand

Joints of the Elbow

The elbow is effectively three joints, consisting of the distal end of the humerus and the proximal ends of the radius and the ulna, and between the humerus and ulna.

The distal end of the humerus presents a rounded capitulum, for the joint with the radius, and a saddle shaped trochlear for the trochlear notch of the ulna.

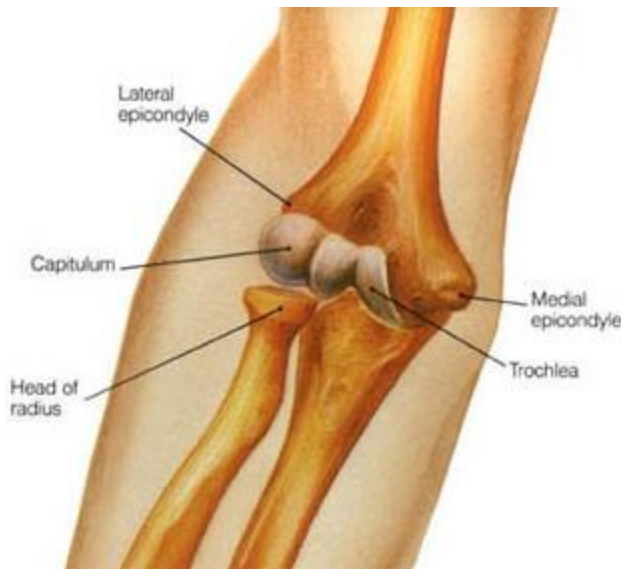

Figure 1 Elbow from front

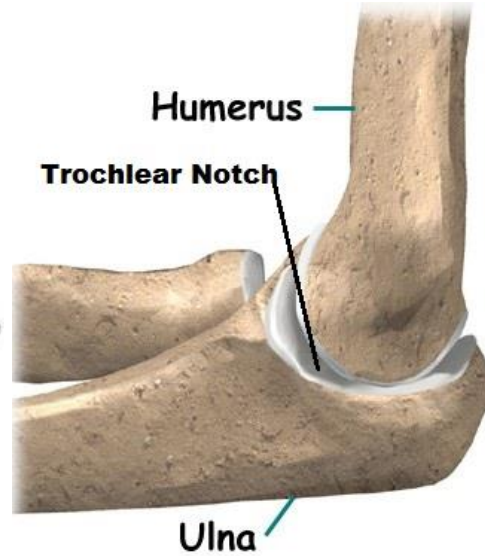


Figure 2 Elbow from medial side

These two joints allow flexion and extension of the elbow. There is also a joint between the radius and ulna. The head of the radius is circular and fits into a hollow concavity at the proximal end of the ulna, forming a pivot joint, allowing supination and pronation of the forearm. The radial head is secured by the annular ligament around the head of the radius. At the distal end of the forearm, the concavity is on the radius, riding around the convexity of the ulna.

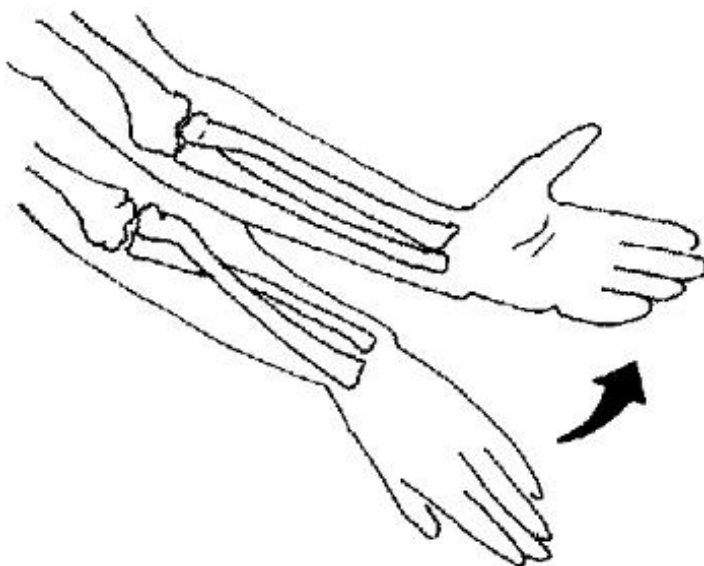

Figure 3 supination and pronation of forearm

Supination is turning the hand so that the palm is facing up. Pronation is the palm facing down.

Joints and ligaments of the elbow

All the joints here are synovial except the interosseous membrane, the syndesmosis, which is fibrous. Movements that take place at the elbow are flexion, extension and rotation. The stability of the elbow (here, between the humerus and the ulna) comes primarily from bony configuration. The trochlear 'fits' into the trochlear notch of the ulna, creating the primary joint allowing flexion and extension. However, as it is a hinge joint, there are medial and lateral collateral ligaments to prevent erroneous medial and lateral movement. There is also a syndesmosis, an interosseous membrane, between the shafts of the radius and the ulna. In addition to these, there is an annular ligament – a ring of tissue around the neck of the radius, holding it in place against the ulna.

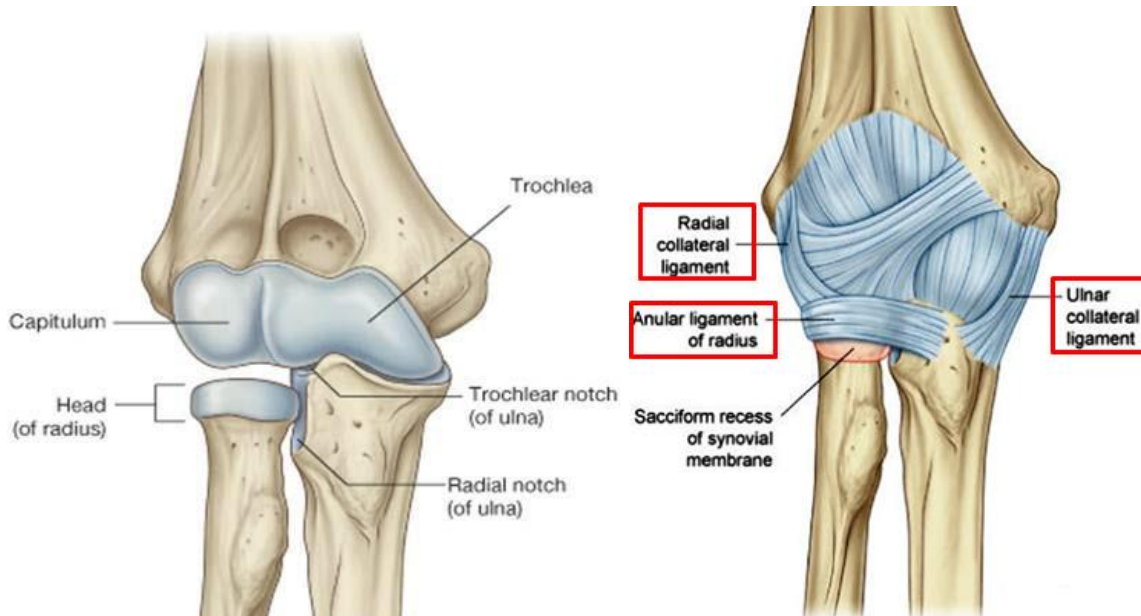
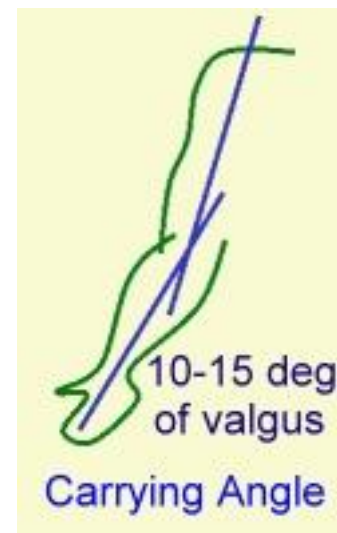


Figure 4 Elbow joint and ligaments

Fig 4 shows the anterior of the elbow with its ligaments. The view on the right shows the lateral collateral ligament from the lateral epicondyle and its association with the annular ligament, which envelops the head of the radius; holding it in place with its pivot joint with the ulna.

The hinge joint allows, from straight to full flexion, some 140° . This movement does not take place around the axis of the humerus. The trochlear is larger than the capitulum, so the axis lies at an oblique angle. With the elbow fully extended, the humerus has an angle of about 170° with the ulna. This is called the carrying angle. The joint between the radius and ulna is a pivot joint and allows about 155° of full supination to pronation. Here it should be mentioned that there is also a pivot joint between the radius and ulna at their distal end as well.

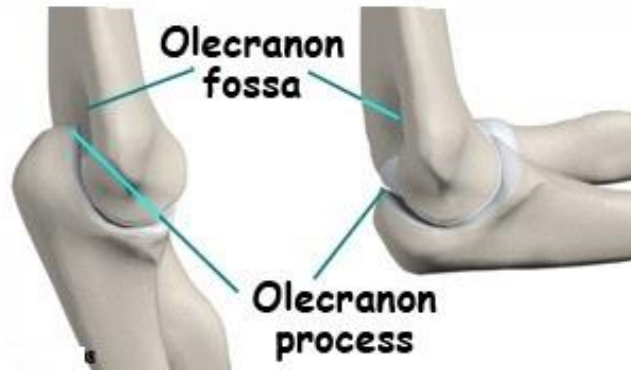Figure 5 The carrying angle



The purpose of the carrying angle is that the elbow 'fits' into the waist when the arm is at the side and is more pronounced in women than men. However, the line of the humerus and the ulna becomes straight when the arm is in its normal working position of almost full pronation.

In full extension the olecranon of the ulna fits into the olecranon fossa, a shallow concavity, of the humerus on the posterior aspect of the humerus and is in line with the epicondyles

Figure 6 Olecranon fossa



Muscles moving the elbow

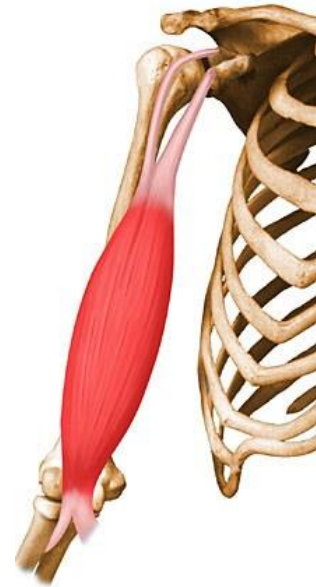Flexors

Biceps Brachii

This has two origins:

- Short head: Tip of coracoid process of the scapula
- Long head: supraglenoid tubercle of scapula. The tendon passes through the glenohumeral joint, then down through the intertubercular groove. This head merges with the short head in the distal third of the arm

Figure 7 Biceps Brachii



It has two insertions:

- The radial tuberosity
- The bicipital aponeurosis inserts into the deep fascia of the forearm
- Action;
- It flexes the elbow and supinates the forearm

Nerve supply - Musculocutaneous

Brachialis

Origin

- Distal half of the anterior humerus

Insertion

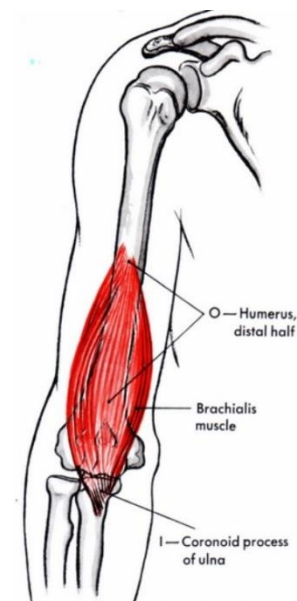
- Anterior surface of the coronoid process of the ulna

Action

- Flexes elbow

Nerve Supply – Musculocutaneous

Figure 8 Brachialis



Brachioradialis

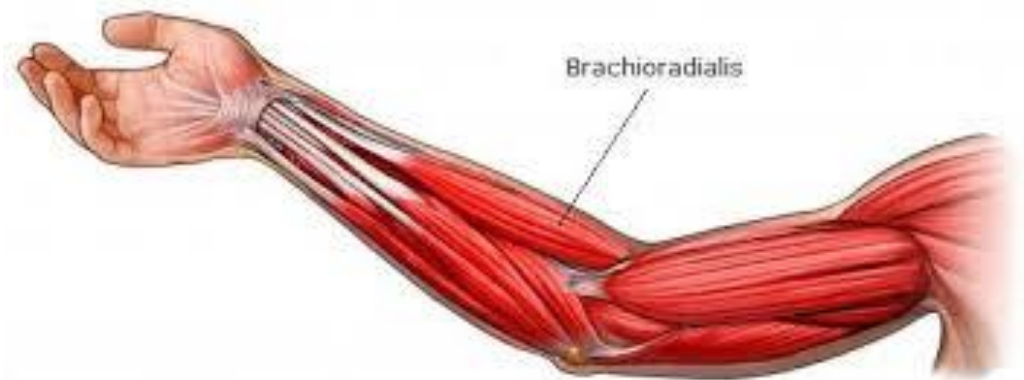


Figure 9 Brachioradialis

Origin

- Upper two thirds of the lateral supracondylar ridge

Insertion

- The styloid process, at the lateral aspect of the distal end of the radius

Action

- Flexes the elbow
- Strongest at mid-pronation
- Can be supinator and pronator depending of position of forearm

Nerve supply – radial nerve

Pronator Teres

Origin

- Common flexor origin at medial epicondyle of humerus
- Coronoid process of ulna

Insertion

- Near the middle of the shaft of the radius

Action

- Flexes the elbow
- Pronates the elbow

Nerve Supply – Median nerve

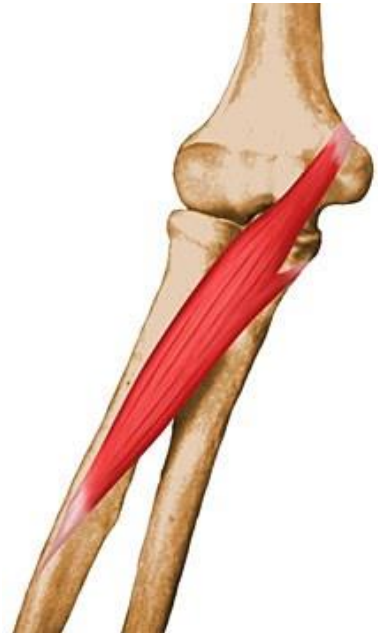
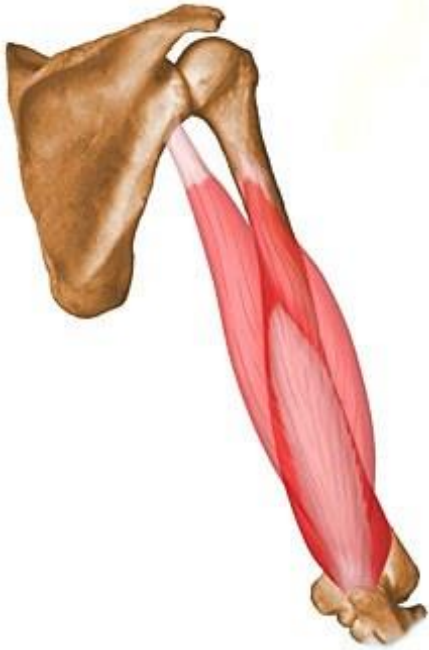
Figure 10 Pronator Teres

Extensors

Triceps



Origin has three heads:

- Lateral head – upper border of radial groove of humerus
- Medial head – humerus below radial groove
- Long head – infraglenoid tubercle of scapula

Insertion

- Olecranon of ulna

Action

- Extension of elbow

Nerve Supply – Radial nerve

Figure 11 Triceps

Supinators

Origin

- Common extensor origin at lateral epicondyle of humerus

Insertion

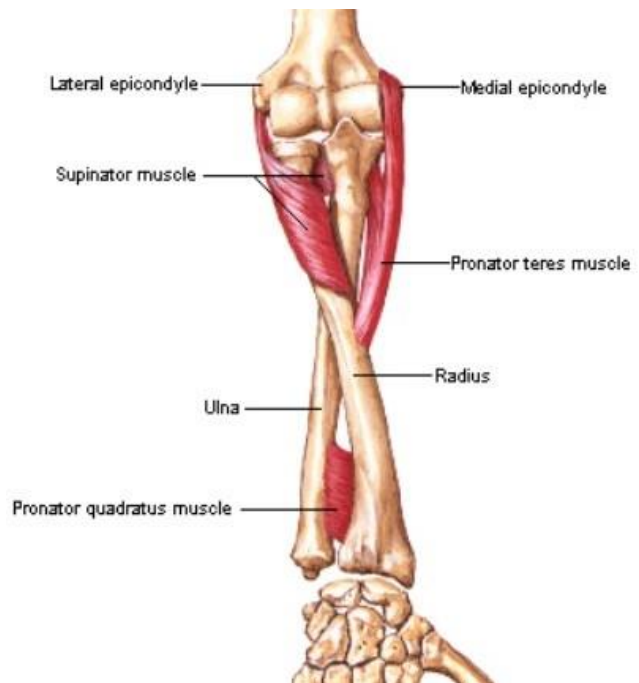
- The fibres pass distally and wrap around the lateral third off the radius

Action

- Supination of forearm

Nerve supply – Radial nerve

Figure 12 Supinator



Biceps Brachii (see above)

Pronators

Pronator Teres (see above)

Pronator quadratus

Origin

- Distal quarter of the ulna

Insertion

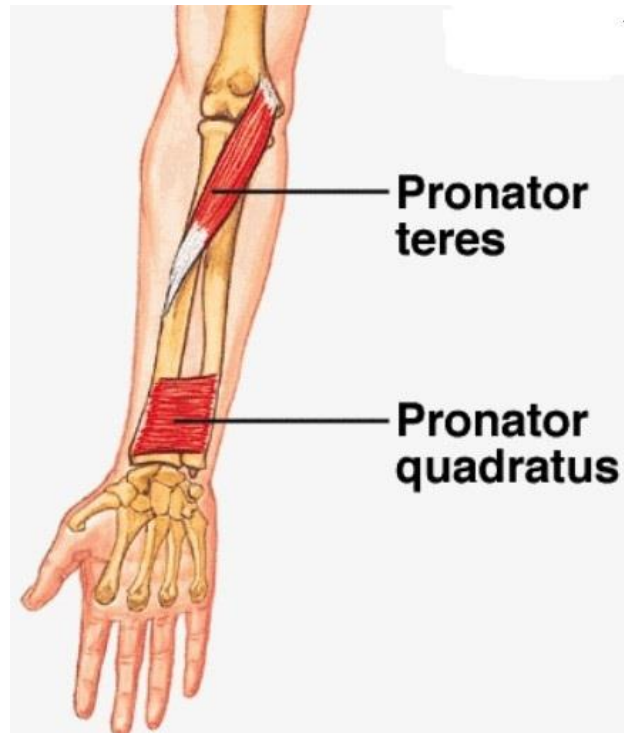
- The square shaped muscle wraps around the radius, so 'rolls' the radius around the ulna

Action

- Pronation of forearm

Nerve Supply – Median nerve

Figure 13 Pronator quadratus



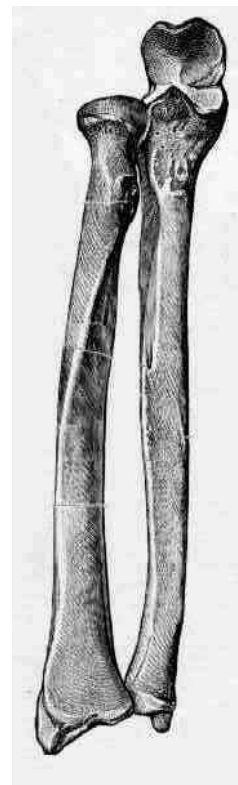
The forearm and wrist may be seen as distinctly separate region, but as there are so many muscles crossing the elbow as well as the wrist, they should be included here.

Bones of the forearm

The bones of the forearm are the radius (here on the left) and the ulna (on the right)

- They are bound tightly together by a syndesmosis, an interosseous membrane
 - This divides the forearm into two compartments: anterior and posterior
- At both proximal and distal ends are pivot joints
 - These allow supination and pronation of the forearm

Figure 14 Bones of forearm

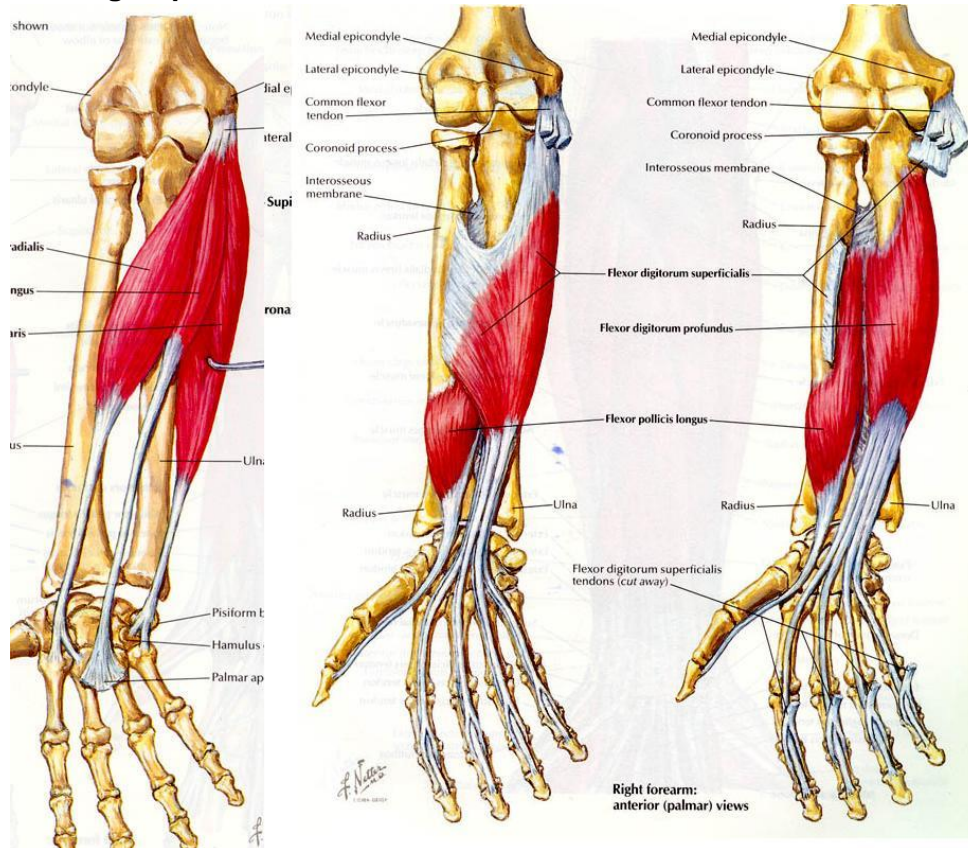


Muscles of the forearm

The muscles of the forearm are divided into two groups: flexor and extensor; divided by the interosseous membrane

The flexor group is divided into three groups, the posterior group into two

Flexor group:



Note all the muscles, bar the one to the thumb all originate from the medial epicondyle: the **common flexor origin**

Superficial Group – Only flex the wrist


- **Flexor carpi radialis** – median nerve
 - Flexes wrist and radial deviates hand
- **Palmaris longus** – median nerve
 - Flexes wrist
- **Flexor carpi ulnaris** – Ulnar nerve
 - Flexes wrist and ulnar deviates hand

Intermediate Group - flex the proximal interphalangeal joint

- **Flexor digitorum superficialis** – Median nerve
 - Flexes fingers at proximal interphalangeal joint

Deep group - flex the distal interphalangeal joint

- **Flexor digitorum profundus** – Median nerve
 - Flexes fingers at distal interphalangeal joint
- **Flexor pollicis longus** – Median nerve
 - Flexes thumb at interphalangeal joint



This creates a potential problem in the hand, as the deeper tendons need to pass by the superficial tendons to their points of insertion. The superficial tendon splits, allowing the deeper tendon to pass through

Figure 16 Flexor tendons in hand

Flexor digitorum superficialis Flexor digitorum profundus

Here the tendons have been separated by a pair of forceps. The profundus tendon can be seen emerging from the split superficialis tendon

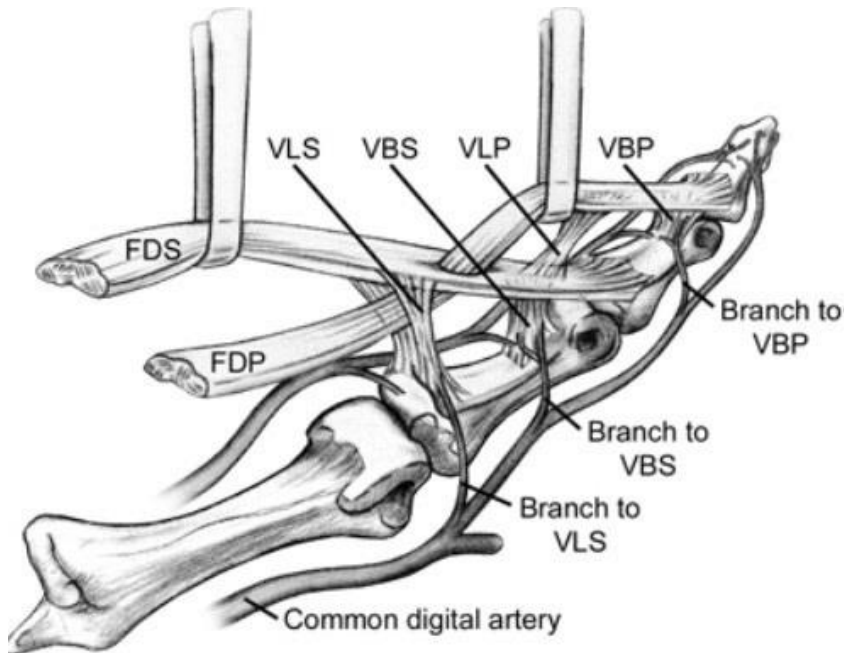


Figure 17 The tendons in the fingers

The tendons pass through the carpal tunnel and up the fingers in their own synovial sheaths.

This arrangement of two sets of muscles on the flexor (volar) aspect of the fingers allows for great dexterity in the movement of the fingers. On the posterior surface of the forearm, there are only two layers of muscles, one of which extend the fingers.

The Extensor Group

Like the flexor group, these muscles mainly originate from an epicondyle, this time the lateral epicondyle, the **common extensor origin**. Here though, unlike the flexor group, the extensors only have two layers

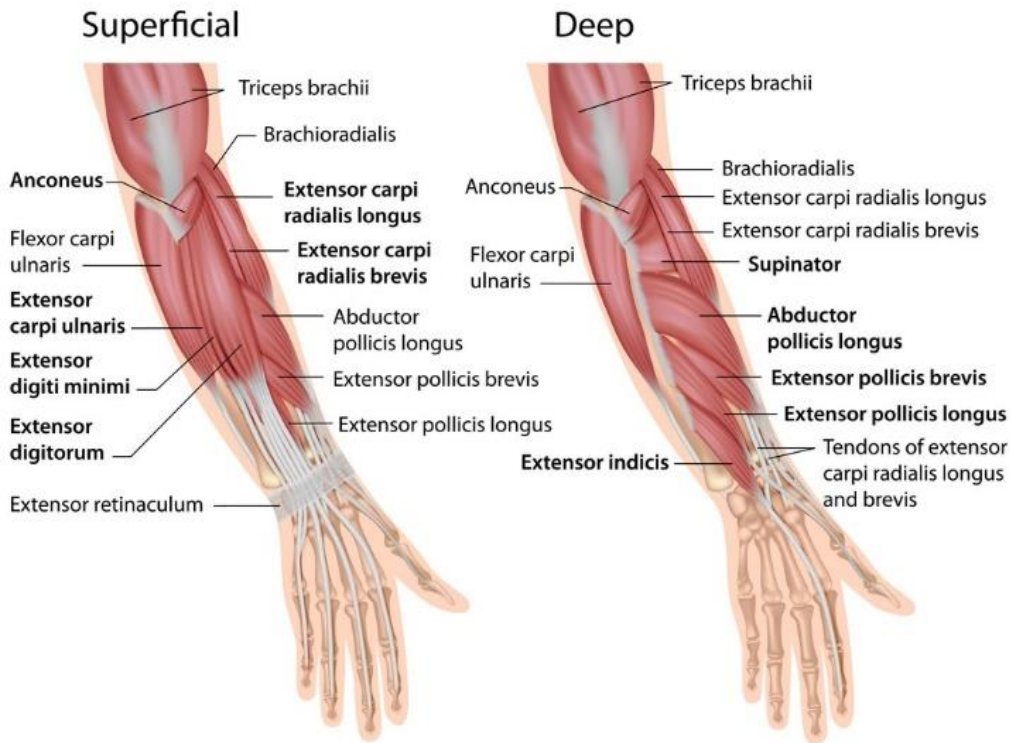


Figure 18
Extensor
muscles of
forearm

Superficial group

- **Anconeus**
 - Extends elbow
- **Extensor carpi radialis longus**
 - Extends and radially deviates hand
- **Extensor carpi radialis brevis**
 - Extends and radially deviates hand
- **Extensor carpi ulnaris**
 - Extends and ulnar deviates hand
- **Extensor digiti minimi**
 - Extends little finger
- **Extensor digitorum**
 - Extends fingers

Deep group

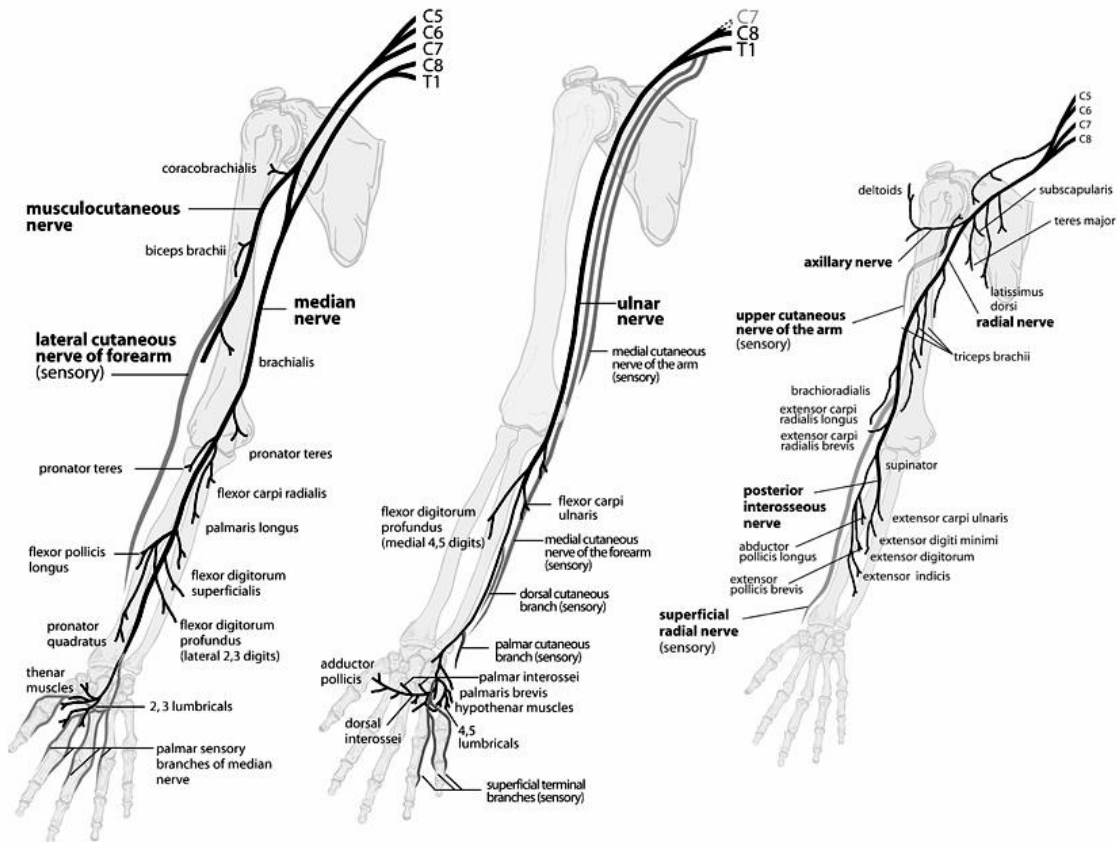
- **Supinator**
 - Supinates forearm
- **Abductor pollicis longus**
 - Abducts thumb
- **Extensor pollicis longus**
 - Extends thumb
- **Extensor pollicis brevis**
 - Extends thumb
- **Extensor indicis**
 - Extends index finger

These are all supplied by the radial nerve, except those with the word 'ulnaris'

Nerves supplying the arm

There are four nerves that supply the arm:

- Musculocutaneous
- Median
- Radial
- Ulnar



Anterior groups of muscles – Nerves and root values

Name	Nerve	Root Values
Biceps Brachii	Musculocutaneous	C5 C6
Brachialis	musculocutaneous	C5 C6
Pronator Teres	Median	C6 C7
Flexor Carpi Radialis Longus	Median	C6 C7
Palmaris Longus	Median	C7 C8
Flexor digitorum superficialis	Median	C7 C8 T1
Flexor digitorum profundus	Median	C7 C8 T1
	Ulnar	
Flexor Carpi ulnaris	Ulnar	C7 C8 T1
Pronator Quadratus	Median	C8 T1
Flexor pollicis longus	Median	C8 T1
	Ulnar	

Abductor Pollicis brevis	Median	C8 T1
Flexor pollicis brevis	Median	C8 T1
Opponens pollicis	Median	C8 T1
Abductor digiti minimi	Ulnar	C8 T1
Opponens digiti minimi	Ulnar	C8 T1
Flexor digiti minimi	Ulnar	C8 T1
Lumbricals	Median	C8 T1
	Ulnar	
Anterior interossei	Ulnar	C8 T1
Posterior Interossei	Ulnar	C8 T1

Posterior groups of muscles – nerves and root values

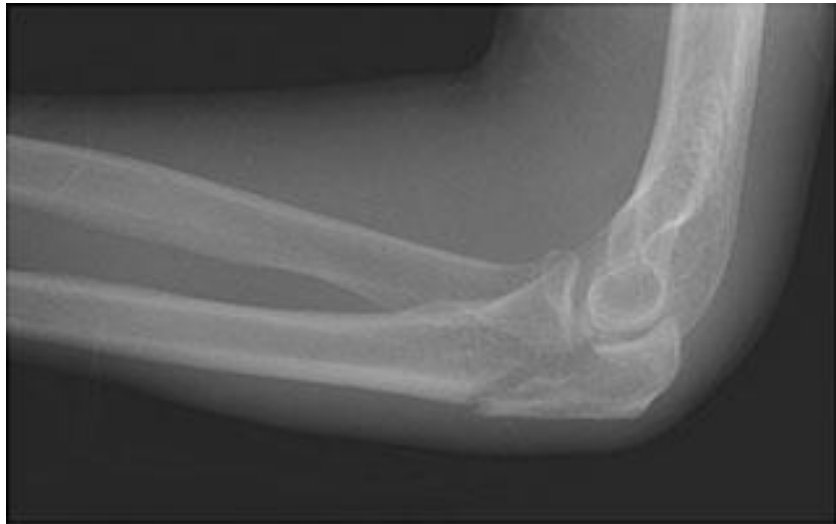Name	Nerve				
Brachioradialis	Radial	C5	C6		
Extensor digitorum	Radial	C5	C6	C7	
Supinator	Radial	C5	C6	C7	
Extensor carpi radialis brevis	Radial	C5	C6	C7	C8
Triceps	Radial		C6	C7	
Extensor carpi radialis longus	Radial		C6	C7	C8
Extensor carpi ulnaris	Radial		C6	C7	C8
Extensor indicis	Radial		C6	C7	C8
Extensor digiti minimi	Radial		C6	C7	C8
Abductor pollicis longus	Radial		C7	C8	
Extensor pollicis brevis	Radial		C7	C8	
Extensor pollicis longus	radial		C7	C8	
Anconeus	Radial		C7	C8	T1

Injuries to Elbow Fractures

These usually are as a result of a fall on the elbow, or from a sudden muscle contraction

Olecranon fractures

Figure 19 Olecranon fracture

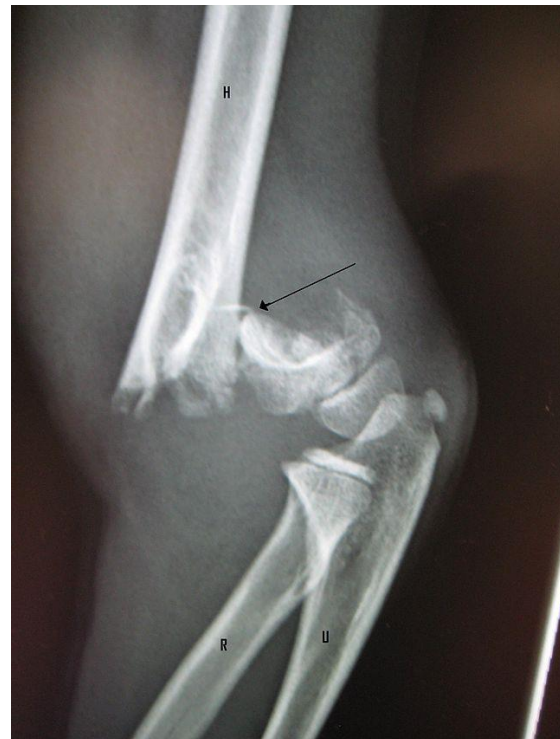

An olecranon fracture usually results from a direct impact injury, like a fall in an adult. As triceps inserts onto the olecranon, the fractured olecranon tends to be displaced. Generally speaking, it is very difficult to regain full range of movement, particularly full extension, after such a fracture.

Supracondylar fractures

In children it can fracture in a different position. According to a website for orthopaedic surgeons, "This is the most common elbow fracture in children, about 60% of fractures in children. It is most common in children <10, peak incidence is between the ages of 5-8 years of age. Primarily in children who are around age 7 years, which is often a period of maximum ligamentous laxity; therefore, the elbow hyperextends when the child tries to catch himself or herself during a fall. During the hyperextension process, the olecranon (elbow bone) process is forced against the weaker, immature metaphyseal bone of the distal humerus, producing the typical extension-type supracondylar fracture

Figure 20 Supracondylar fracture



One example of this occurring is on trampolines, where several children are bouncing on it at the same time. If a child falls, the elbow is the primary point of contact with significant challenge to any regions of ossification. It is usually treated via surgical internal fixation and physiotherapy.

If the region of fracture is higher on the humerus, it may upset the course of the radial nerve in the spiral groove, leading to 'wrist drop'.

Avulsion fractures

Another type of fracture in this region is an avulsion fracture.

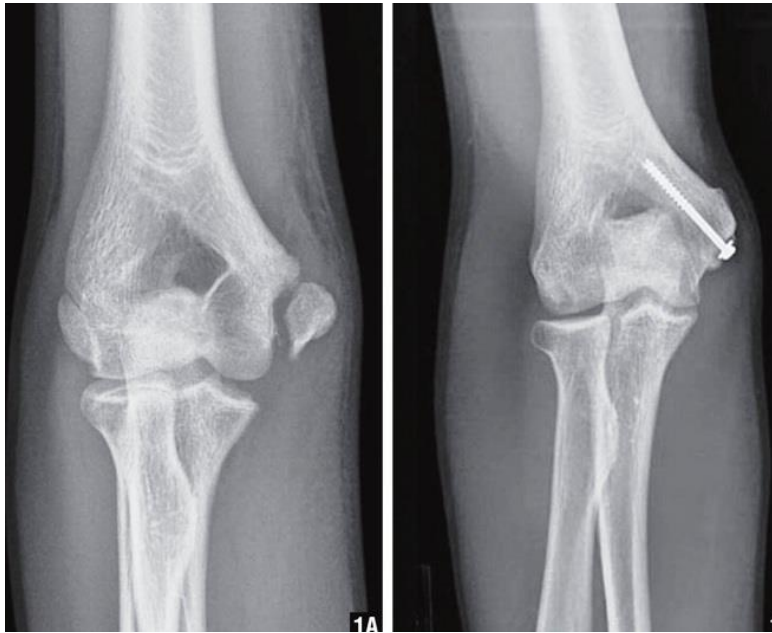


Figure 21 Avulsion fracture of medial epicondyle

This figure shows an avulsion fracture of the medial epicondyle of the left elbow. In this case it can be caused by a repetitive or sudden strain injury. The sudden contraction of the muscle 'pulls' off a lump of bone at its point of attachment. If the fracture is 'fresh', there will probably be bruising and swelling around the joint.

A repetitive stress injury (RSI) is an overstress injury that results from repetitive valgus distraction forces on the medial elbow. Such forces are commonly generated during repetitive throwing motions. Repeated stress or microtrauma leads to overuse injury when the tissue damage exceeds tissue repair. The type of injury depends on the skeletal maturity. Common conditions included in this syndrome are medial apophysitis, medial epicondylar avulsion fracture, and ulnar collateral ligament injury. Compression injury to the capitulum and radial head can also occur.

Dislocations

Dislocations can occur in the elbow region with different types for adult and paediatric cases.

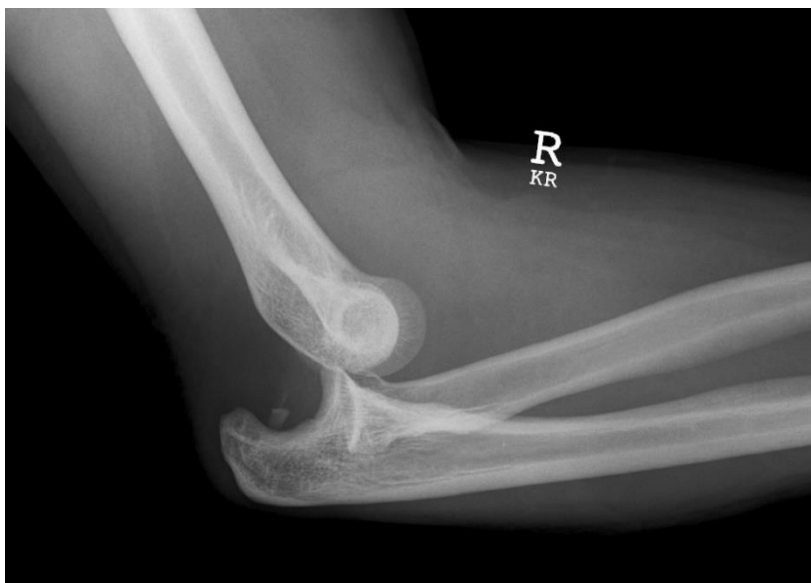

Figure 22 Dislocation of humero-ulnar joint

Elbow dislocations are not common. Elbow dislocations typically occur when a person falls onto an outstretched hand. When the hand hits the ground, the force is sent to the elbow. Usually, there is a turning motion in this force. This can drive and rotate the elbow out of its socket. Elbow dislocations can also happen in car accidents

when the passengers reach forward to cushion the impact. The force that is sent through the arm can dislocate the elbow, just as in a fall.

- A **simple dislocation** does not have any major bone injury.
- A **complex dislocation** can have severe bone and ligament injuries.

In the most **severe dislocations**, the blood vessels and nerves that travel across the elbow may be injured. If this happens, there is a risk of losing the arm.

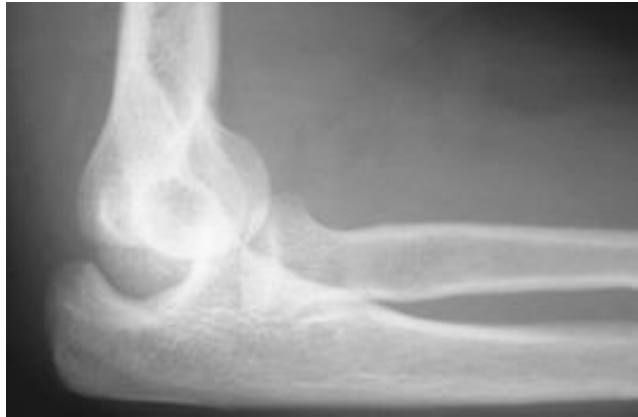


Figure 23 Partial dislocation

Some people are born with greater laxity or looseness in their ligaments. These people are at greater risk for dislocating their elbows. Some people are born with an ulna bone that has a shallow groove for the elbow hinge joint. They have a slightly higher risk for dislocation.

These can be reduced without surgery but need to be performed gently with pain reduction.

Radial head dislocation

Dislocations can occur of the radial head from the annular ligament. This is usually the case with young children

This is the most common traumatic injury of the elbow in children. It is also known as "pulled elbow" or "nursemaid's elbow." The average age of incidence is 2-4 years. As children get older, the annular ligament gets thicker and resists tearing, making this injury less likely.

Note in these pictures, the lines representing normal.

Figure 24 Elbow joint line - Normal

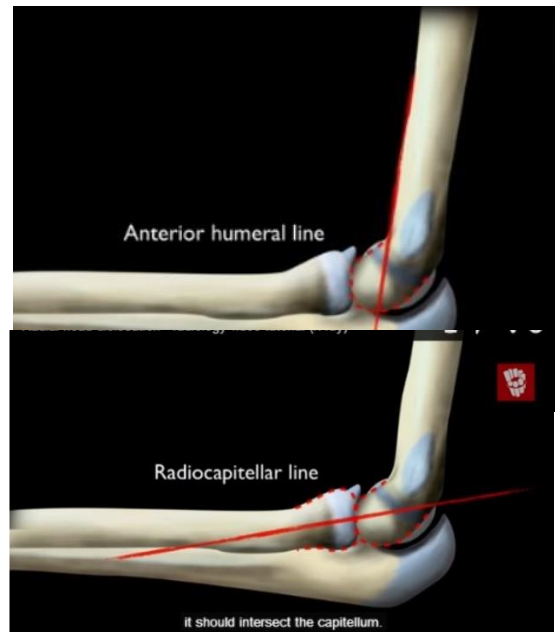
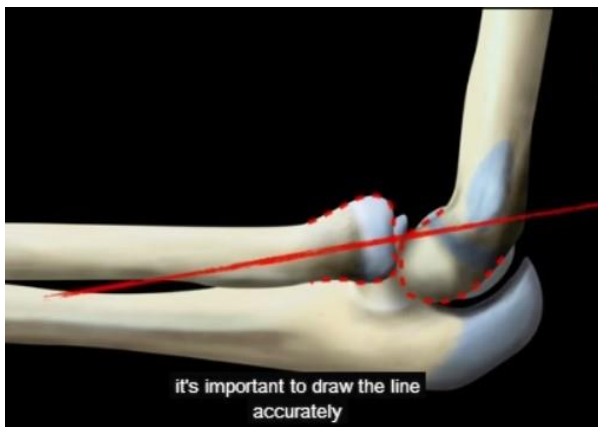
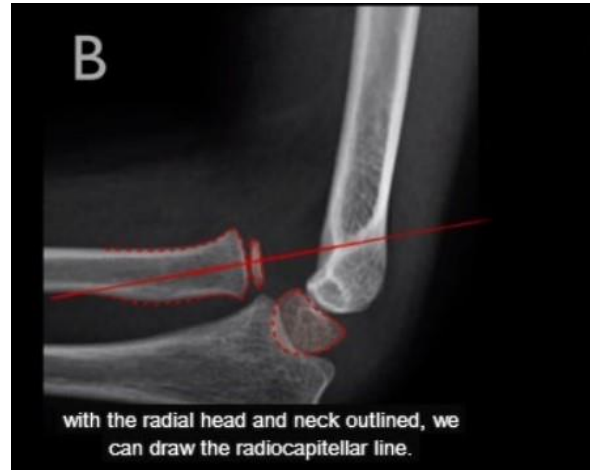


Figure 25 Dislocated radial head - schematic

The injury results from a pull on the extended pronated arm. The annular ligament tears at its attachment to the radius and the radial head moves distally. As the traction is relieved, the annular ligament gets caught between the radial head and the capitulum.

The diagnosis is a clinical one. Radiographs can be obtained to rule out other injuries.

Figure 26 Dislocation of radial head - X-ray



Treatment entails reduction of the subluxation by forcefully supinating the forearm with the elbow flexed 60 to 90 degrees. The child should be observed following reduction as he/she should use the arm shortly after the subluxation is reduced.

It can manifest as:

- Pain
- The child will be holding the affected arm in a part-flexed, pronated position against their side
- On examination, there may be a palpable gap just distal to the lateral epicondyle

It can be reduced:

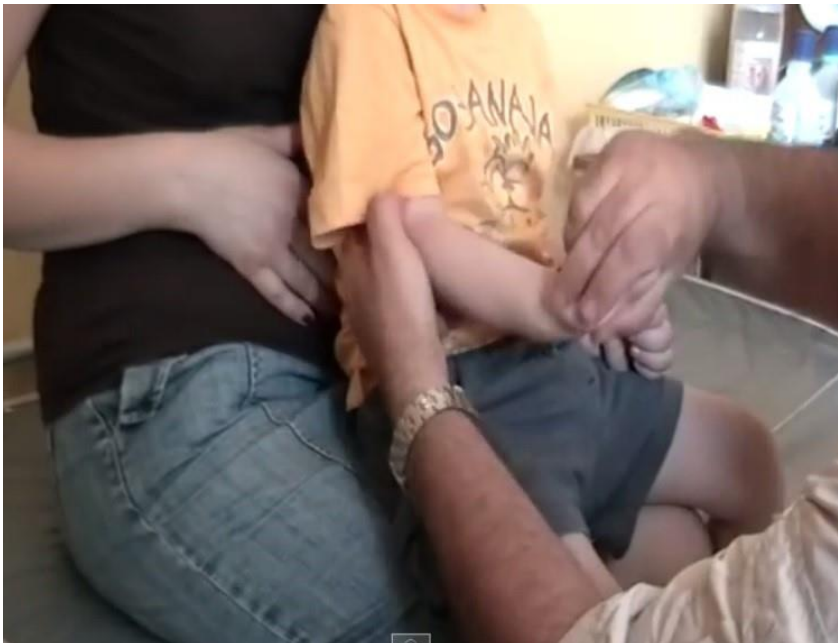

Figure 27 Relocation of radial head

- Flex the wrist to 90°
- Support the elbow
- 'Hold hands' with the affected arm
- Locate the head of the radius
- Gently compress long the axis of the forearm
- Encourage relocation with repeated small amounts of supination/pronation, but with an overall supination of the forearm

Distal Biceps Tendon Rupture

In the shoulder section we described the rupture of the tendon of the long head of biceps (bicipital tendon). The tendon at its distal end, at the insertion, can also rupture.

Figure 28 Ruptured distal tendon of biceps

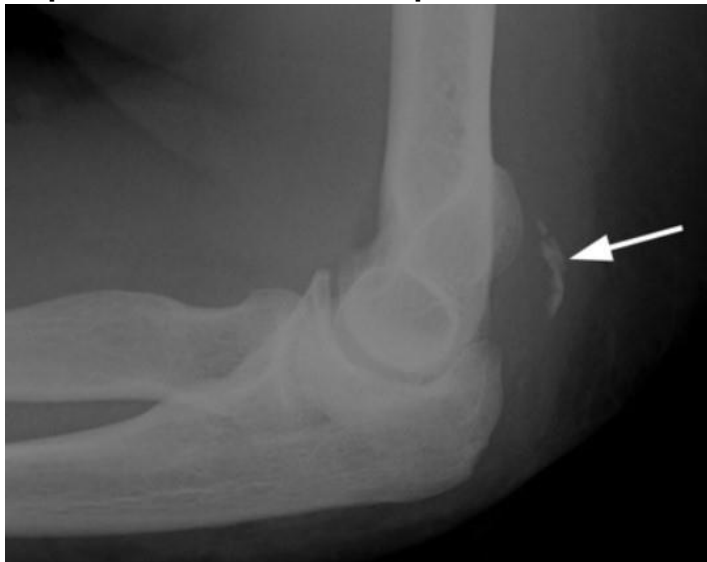

Such a tendon injury can be seen here in this man's right arm. Note the uniform curvature of the muscle outline of his left arm, and the shortened muscle curvature of his right.

This injury can occur when there is sudden extension whilst contracting the biceps. There will be sudden onset pain with swelling in the elbow/forearm. Weakness with flexion will be noted, with the x-rays often being normal.

In most cases surgical repair is required

Rupture of Distal end Triceps



This results from sudden flexion when the elbow is extended.

Figure 29 Ruptured triceps tendon

This X-ray shows a flake of bone, demonstrating an avulsion injury. There will be swelling, pain and weakness.

Surgical repair will be indicated

Repetitive Strain injuries at Elbow

These are usually seen as local injuries, and they may well be. However, it is important to see them in terms of the whole person and how they move. People can point to where the pain is and expect you to go there and take it away. Here it is also important to look at the shoulder and neck to check for tension patterns, especially for myofascial tension patterns around the scapulae, changing how the person moves their arms. Included here should be affecting factors from elsewhere; one thing to consider is referred symptoms from visceral elements. Pathology or dysfunction from below the diaphragm can refer back up to the neck and shoulders. Obvious ones here are liver and gall bladder pathology, which can both refer to

the right shoulder giving pain there. The mechanics of this is via the phrenic nerve, which descends from the cervical spine in our embryological development. For example, the liver can create referred symptoms:

- C4-5 right side or bilateral
- Right scapula
- Right glenohumeral peri-arthritis
- Cervical/brachial plexi and associated fascia
- T7-10
- R 7-10 lower ribs and costovertebral articulations
- Cranial base restrictions – right side
- Left sciatica – venous hepatic origin
- Right sciatica – related to restrictions of: hepatic fascia, right kidney, ascending colon

It may not even create blatant, overt, symptoms there. It may create subliminal referrals, such that the person is aware of 'something going on' and begin to react to it with local tension and guarding in the muscles. This brings out a gradual change in how the person moves and responds, such that there are knock on effects in the mechanics further down the arm. Any of these concepts can be confusing to the patient as they tend to think in singulars; what was the *one* thing they did to cause this suffering

Common Extensor Origin (CEO) (aka tennis elbow, lateral epicondylitis, lateral epicondylalgia)

The term tennis elbow is most commonly used, but it is hardly appropriate for people who do not play tennis. The term epicondylitis is also commonly used but has been questioned, as there is no evidence of periostitis (inflammation of the periosteum, to which the tendon attaches). Ferre used the term epicondylalgia in 1897, as the condition was not always inflammatory, just painful. The mechanism by which it occurs, and its pathology have always remained an enigma.

Generally:

- Abnormal tension is found on a normal joint
- Normal tension is found on an abnormal joint
- Normal stress on a normal joint when that joint is neither prepared nor accustomed to that activity

Many theories have been postulated as to its occurrence, but a few points may be considered:

- Tendons are avascular and their strength comes from their density. The symptoms of acute inflammation may not all apply here (i.e. no swelling, as there is no intercellular space to allow it). Persistent trauma to a tendon may result in an inflammatory process, which (over weeks, months or years) will result in an increase in the diameter of the tendon. This will result in a decrease in its strength and possibly predispose to the maintenance of the injury
- You may remember from your physics that if a wire is stretched that the tension will express itself at the ends. Applying this principle to a hypertensive muscle (or more specifically, the fascia around that muscle), this will be the tendons, or the musculotendinous junction.
 - This same principle can be applied to the continuum of fascia around the arm down from the shoulder, with any myofascial tension patterns there.

- An early hypothesis was that epicondylitis was a traction injury to the periosteum from the muscles that attach to the lateral epicondyle, although periostitis has never been confirmed
- A tear in the proximal body of the extensor group has also been considered (with this theory supporting the manipulation of the CEO)

This condition is rarely seen in people under 20 and people over 60 years of age and is most common between the ages of 35 – 50. It occurs equally in both males and females but is more prevalent in the dominant arm.

[NB to grip an object the primary muscles being the used are the flexors and the theory says that the antagonistic group (the extensors) **should** relax. However, all joint movements are controlled over their full arc of movement by graded contraction and relaxation of both agonists and antagonists. Hence in the wrist, to brace the wrist in activity, both flexors and extensors are active. If this situation of bracing the wrist during activity is persistent, then hypertension of both groups will occur. This also supports the hypothesis of myofascial tension patterns in the neck and shoulder expressing themselves in the elbow (but necessarily from nerve irritation).

Symptoms

- Pain on the lateral epicondyle
- Loss of strength in extensor group

Causative and aggravating factors

- Repetitive activities of the wrist and elbow
- Muscular activity including squeezing
- Extreme wrist positions
- Cervical radiculopathy (nerve root irritation in the neck)

People affected

- Meat processing industry
- Packaging
- Cleaning work

On examination there will be pain on palpation of the lateral epicondyle and there will be hypertension in the extensor group of forearm muscles

Treatment

- Rest from the activity during the acute phase
- Massage (deep friction) of the extensor muscles
- Faradic and ultrasound may be efficacious
- 'Homework' of friction with ice cube massage can be demonstrated
- NSAI's
- Local steroid injection
- Local manipulation to tendon
- Check and address any visceral elements
- Check and address any periscapular fascial elements
- Check and address any cervical hypertension and fascial elements

Common Flexor Origin (aka golfer's elbow)

This is the equivalent condition on the medial side of the elbow; so called golfer's elbow because from the grip and follow through elements of the golf swing

Symptoms

- Pain on the medial epicondyle
- Loss of strength in the flexor group

Causative/aggravating factors

- As tennis elbow
- Sport (golf?)

People affected – as tennis elbow

On examination there will be pain on the medial epicondyle with hypertension in the flexor group of muscles

Wrist drop

This is not a condition of the elbow, per se, but can be caused by conditions around the elbow. It is a condition when the person cannot extend the wrist and it caused by insult or pressure to the radial nerve, which supplies triceps and the extensor group of muscles in the posterior forearm.

*The **radial nerve** is a nerve that arises from the brachial plexus, originating from the posterior cord of the brachial plexus, carrying fibres from the ventral roots of spinal nerves C5, C6, C7, C8 and T1. From here it travels posteriorly through what is often called the triangular space, the lower triangular space of the axilla*

*The overall 3D shape of the axilla looks slightly like a **pyramid**. The borders consist of four sides and a base with an opening at the apex.*

- **Apex** – Also known as the axillary inlet, this is formed by lateral border of the first rib, superior border of scapula, and the posterior border of the clavicle.
- **Lateral wall** - Formed by intertubercular groove of the humerus.
- **Medial wall** - Consists of the serratus anterior and the thoracic wall (ribs and intercostal muscles).
- **Anterior wall** - Contains the pectoralis major and the underlying pectoralis minor and the subclavius muscles.
- **Posterior wall** - Formed by the subscapularis, teres major and latissimus dorsi.

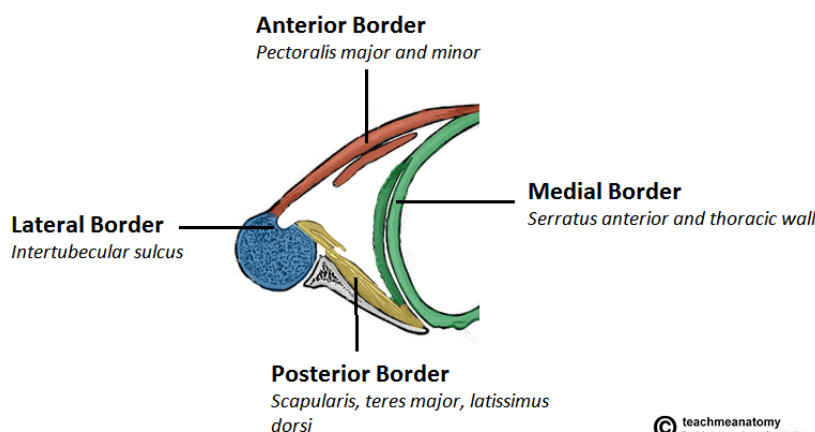


Figure 30 the axilla

The radial nerve emerges between the heads of teres major, latissimus dorsi and the long head of triceps and supplies the medial, lateral, and long heads of the triceps muscle of the arm (as it passed through the spiral groove of the humerus). It then pierces the fascia of the extensor compartment of the forearm and supplies all 12 muscles in the posterior osteofascial compartment of the forearm and the associated joints and overlying skin.

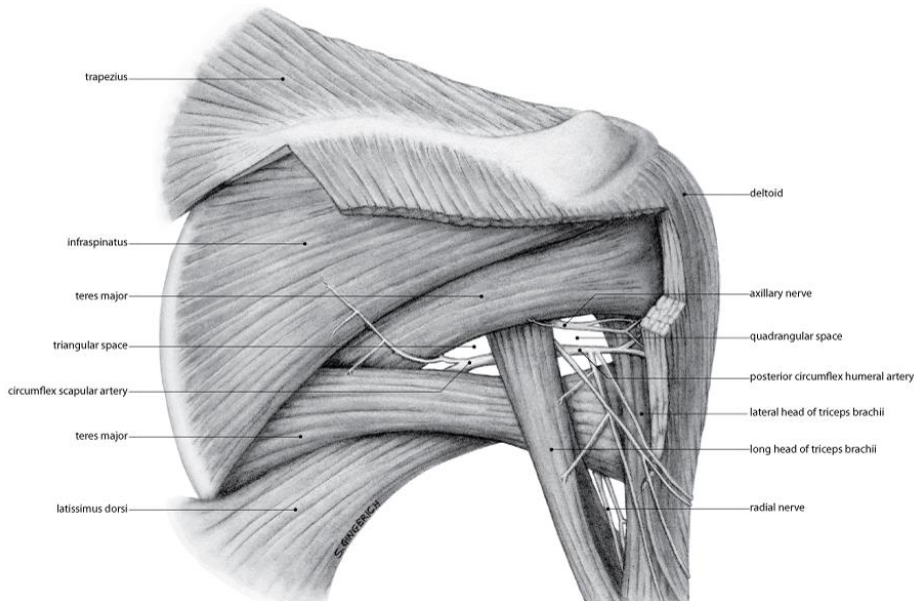


Figure 31 Posterior axilla showing triangular space

The radial nerve and its branches provide motor innervation to the posterior arm muscles (the triceps and the anconeus) and the extrinsic extensors of the wrists and hands; it also provides cutaneous sensory innervation to most of the back of the hand. The ulnar nerve provides cutaneous sensory innervation to the back of the little finger and adjacent half of the ring finger.

The radial nerve divides into a deep branch, which becomes the posterior interosseous nerve, and a superficial branch, which goes on to innervate the dorsum (back) of the hand. As it emerges between the muscles of the posterior axilla, this posterior axilla will always need attention.

Symptoms

- *The person may complain of pain over the lateral epicondyle, similar to tennis elbow. They will also complain of weakness in pulling the wrist into extension*
- *The degree of weakness varies, and can range from weakness on active resisted movement to a blatant 'paralysis' situation*

Treatment

- *Myofascial release to the latissimus dorsi in the region of the inferior angle of the scapula, here including teres major and the relationship between the two*
- *Address any tension patterns in the posterior axilla*
- *Massage of related muscle groups:*
 - *Triceps*
 - *The extensor group of the forearm*
 - *Friction of groups close to the CEO*
 - *Ultrasound to the CEO region*

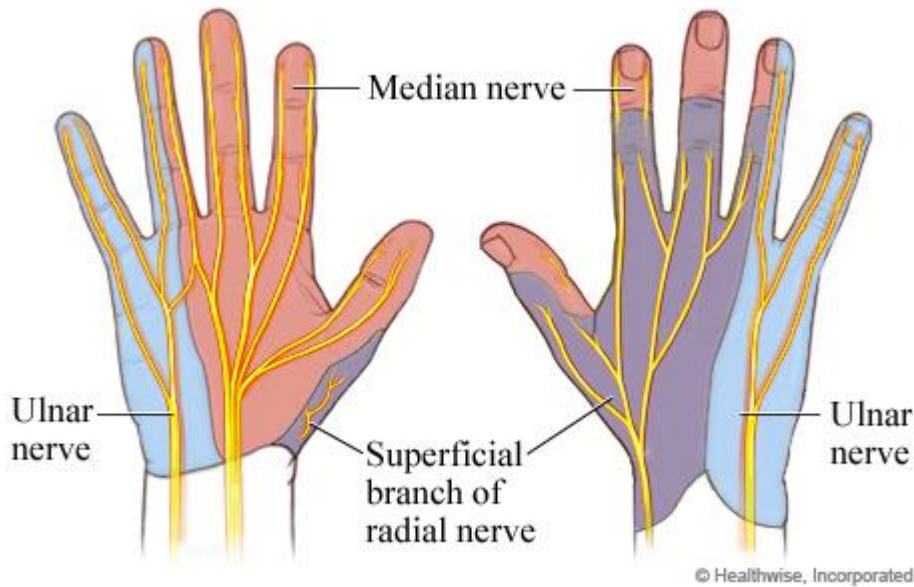


Figure 32 Sensory nerve distribution in hand

Ulnar Nerve Entrapment at the Elbow (Cubital Tunnel Syndrome)

Ulnar nerve entrapment occurs when the ulnar nerve in the arm becomes compressed or irritated.

Its course is:

- It emerges from the neck at C8 and T1
- It passes between the scalene muscles in the side of the neck
- It rests on top of the first rib (where the anterior and middle scalene muscles attach)
- It passes down the medial side of the arm
- It then passes behind the medial epicondyle in the cubital tunnel
- It supplies medial carpal muscles in the forearm
- It enters the wrist and hand via Guyon's tunnel
 - Between the hamate and pisiform
- It supplies the muscles of the hypothenar eminence and intrinsic muscles of the hand
- It also supplies the skin over the little finger and medial side of the ring finger

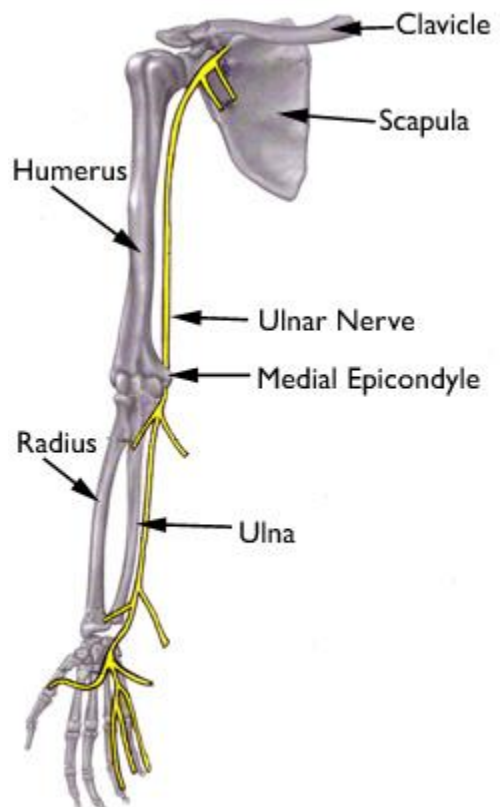
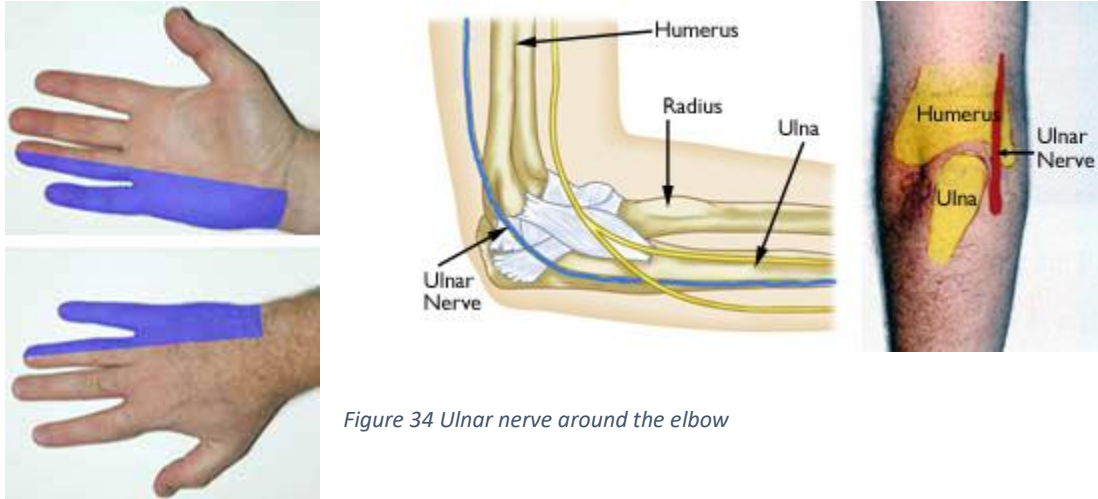


Figure 33 Ulnar nerve distribution



Cause

In many cases of cubital tunnel syndrome, the exact cause is not known. The nerve is especially vulnerable to compression at the elbow because it must travel through a narrow space with very little soft tissue to protect it.

Common Causes of Compression

There are several things that can cause pressure on the nerve at the elbow:

- When the elbow is bent, the ulnar nerve stretches around the bony ridge of the medial epicondyle.
 - This can irritate the nerve, keeping the elbow bent for long periods or repeatedly bending the elbow can cause painful symptoms.
 - Sleep with their elbows bent can aggravate symptoms of ulnar nerve compression and waken a person up at night with numbness
- In some people, the nerve slides out from behind the medial epicondyle when the elbow is bent. Over time, this sliding back and forth may irritate the nerve
- Leaning on the elbow for long periods of time can put pressure on the nerve
- Fluid build-up (swelling) in the elbow can cause swelling that may compress the nerve.
- A direct blow to the inside of the elbow can cause pain, electric shock sensation, and numbness in the little and ring fingers.

Risk Factors

Some factors put you more at risk for developing cubital tunnel syndrome. These include:

- Prior fracture or dislocations of the elbow
- Bone spurs/ arthritis of the elbow
- Swelling of the elbow joint
- Cysts near the elbow joint
- Repetitive or prolonged activities that require the elbow to be bent or flexed

Symptoms

Cubital tunnel syndrome can cause an aching pain on the inside of the elbow. Most of the symptoms, however, occur in the hand.

- Ulnar nerve entrapment can give symptoms of "falling asleep" in the ring finger and little finger, especially when the elbow is bent. In some cases, Numbness and tingling in the ring finger and little finger are common symptoms of ulnar nerve entrapment.

- Often, these symptoms come and go. They happen more often when the elbow is bent, such as when driving or holding the phone. Some people wake up at night because their fingers are numb
- It may be harder to move the fingers in and out, or to manipulate objects.
- Weakening of the grip and difficulty with finger coordination (such as typing or playing an instrument) may occur.
- These symptoms are usually seen in more severe cases of nerve compression.
- If the nerve is very compressed or has been compressed for a long time, muscle wasting in the hand can occur.
 - Once this happens, muscle wasting cannot be reversed. For this reason, it is important to see a doctor if symptoms are severe or if they are less severe but have been present for more than 6 weeks.

Home Remedies

- Avoid activities that require you to keep your arm bent for long periods of time.
- If a computer is used frequently, make sure that the chair is not too low.
 - Do not rest your elbow on the armrest.
- Avoid leaning on elbows or putting pressure on the inside of your arm.
 - For example, do not drive with the arm resting on the open window.
- Sleep with a towel wrapped around the arm at night to keep it straight

Osteochondritis Dissecans

This is rare condition when there is a loose body, a fragment of articular cartilage, in the joint space causing dysfunction within the joint. It occurs in children and youths who still have ***open growth plates***.

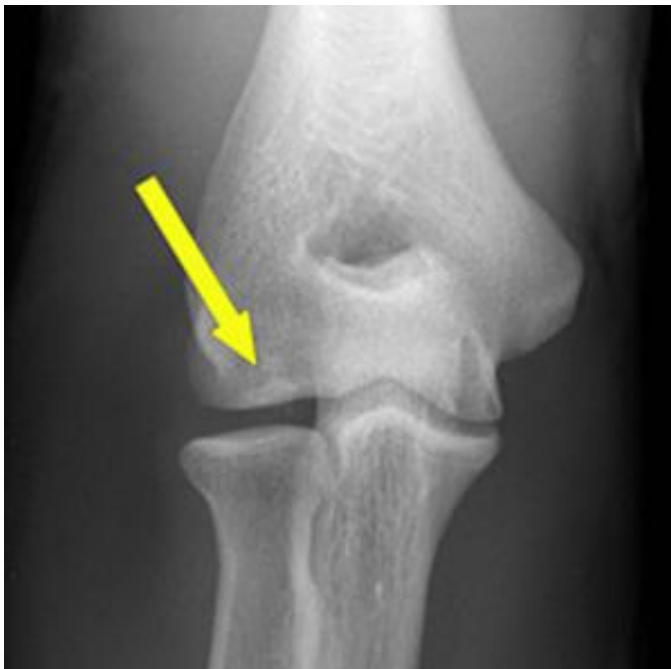

Figure 35 osteochondritis dissecans

This X-Ray show how they are not so easily seen without the experience eye. There may be no distinct loose fragment as such.

Panner's Disease

Panner's disease involves the growth plate in the elbow (growth plates produce new bone tissue and determine the final length and shape of bones in adulthood). The disease occurs in kids who are younger than age 10, typically young athletes, and usually affects the dominant arm.

Panner's disease is part of a family of bone development diseases that occurs in kids and teens.

Risk factors:

- **Age.** Osteochondritis dissecans occurs most often in people between the ages of 10 and 20, with the average age around 11.
- **Sex.** Males are more likely to develop osteochondritis dissecans than are females.
- **Sports participation.** Sports that involve jumping, throwing and rapid changes in direction may increase your risk of osteochondritis dissecans.

Symptoms

- The person will present with limitation with limitation of elbow movement, sometimes associated with locking of the joint, and with pain and swelling

Treatment

- Surgery can be indicated to remove or reattach the loose fragment

Degenerative conditions

Degenerative conditions of the elbow are essentially arthritic ones: osteoarthritis or rheumatoid arthritis.

Osteoarthritis

Osteoarthritis is also commonly known as 'wear and tear', though the dividing line between the two is nebulous

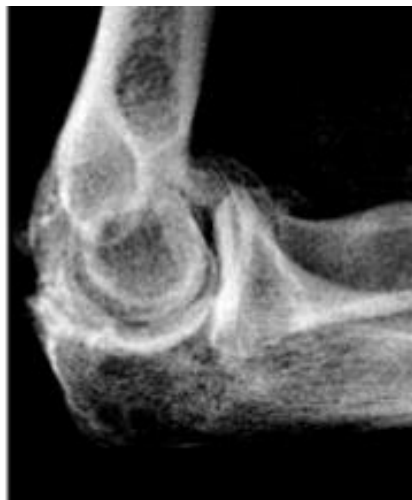
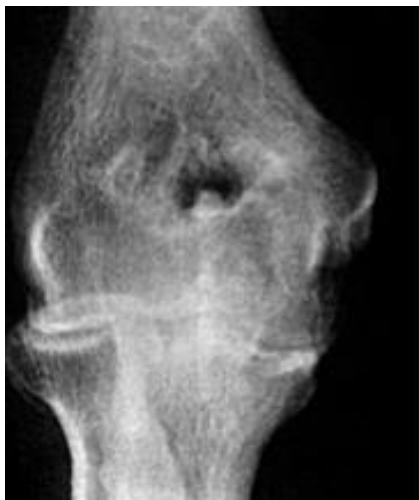

Figure 36 Osteoarthritis of elbow

Fig 35 Shows an X-ray of an arthritic elbow. Note the loss of clarity of the joint lines and the osteophytes seen as 'hazy' bone on the front and back of the joint.

These osteophytes will

result in limitation of the range of movement of the joint.

Mechanism of injury

- This is open to debate, as degenerative changes is not necessarily indicative of increased use. It may well be indicative of increased, persistent, fascial tension patterns across the joint
- There may be traumata (major and minor, possibly repetitive, traumata)
- A history of osteochondritis dissecans or other secondary to other metabolic joint disease (like rheumatoid arthritis)

Symptoms

- Pain, stiffness and locking
- X-rays will show osteophyte formation and loss of joint space

Treatment

- Rest, physical or physiotherapy
- NSAI's as required
- Advice on activity

Manipulations of the Elbow

Radial Head (e.g. of right elbow)

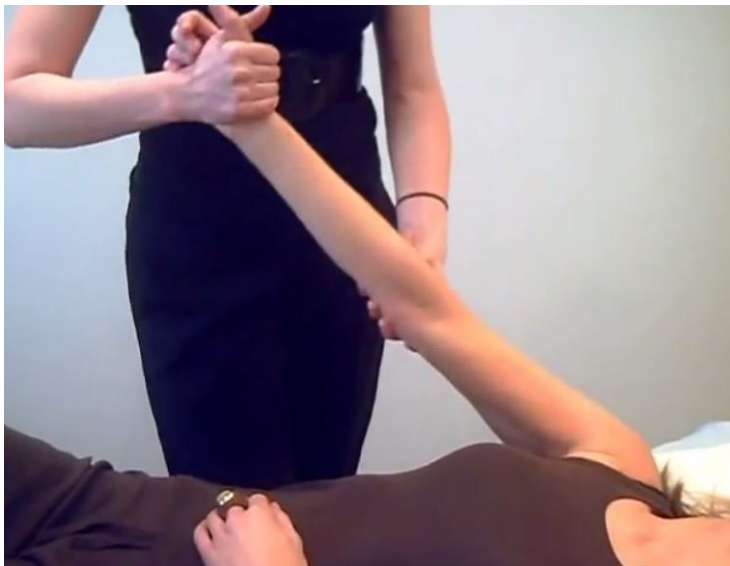

Figure 37 HVT radial head

Supine:

1. Hold their right hand, with your right hand, from its palmar side
2. Localise the lateral aspect of the radial head with the thumb of your left hand
3. Slowly take the elbow into full extension, feeling the radial head with your thumb
4. Optimise the tension with varying supination and pronation of the forearm
5. Thrust on the radial head pushing it anterior

Sitting

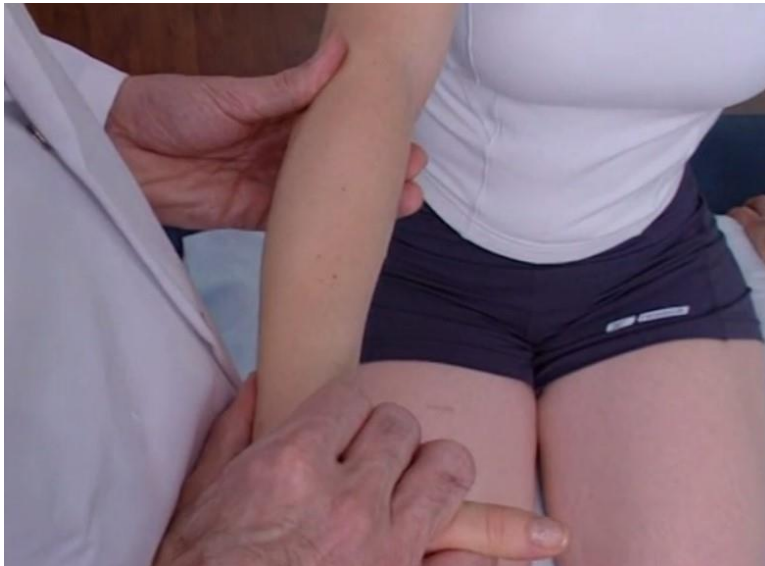

Figure 38 HVT radial head - 2

1. Hold their right hand, with your right hand, from its dorsal side, linking their thumb with your little finger
2. Localise the lateral aspect of the radial head with the thumb of your left hand
3. Slowly take the elbow into full extension, feeling the radial head with your thumb
4. Optimise the tension with varying supination and pronation of the forearm
5. Thrust on the radial head pushing it anterior

Common Extensor Origin

There can be a development of fibrous tissue in the common extensor muscles due to fascial adaptations. These can be broken down:

1. Locate the common extensor origin
2. Follow the tendon a little distally and fix there
3. Get the patient to slowly flex and extend the wrist whilst you fix on this region
 - a. It might/will precipitate some 'good' pain
4. Repeat several times



Figure 39 Muscle energy technique to extensor group

Wrist and Hand

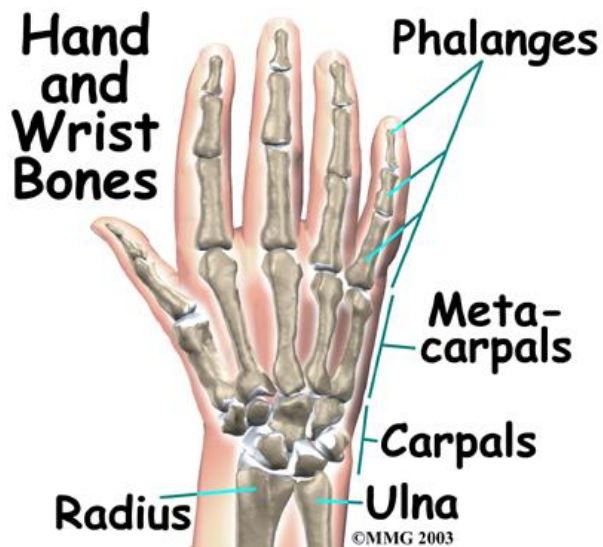

Figure 40 Bones of wrist and hand

The wrist and hand can be seen as one, but we'll look at them separately.

The Wrist

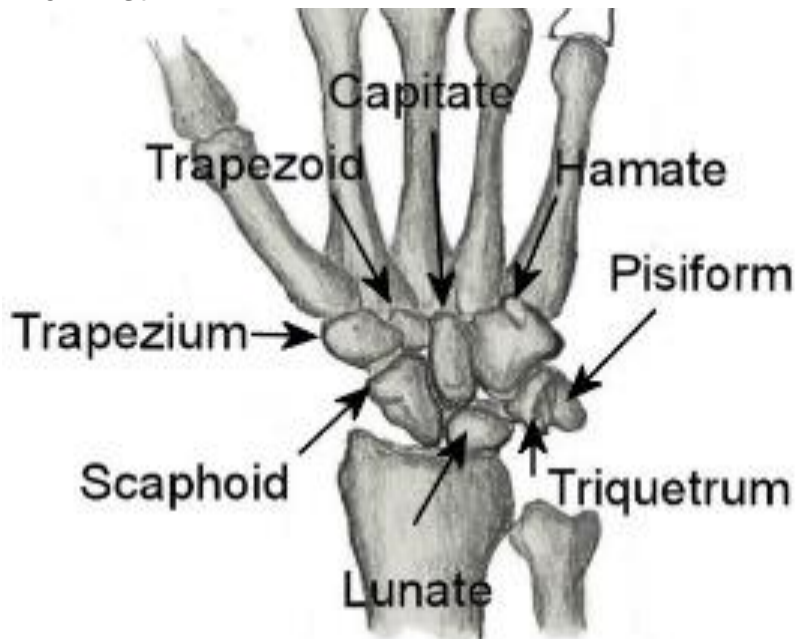


Figure 41 Wrist bones

Bones

The bones of the wrist are:

Proximal row:

- **Scaphoid, lunate, triquetral, pisiform**

Distal row

- **Hamate, capitate, trapezoid, trapezium**

Remembering the bones of the wrist can be a problem, so a mnemonic can be of use, using the initial letters of the bones. One used is seeing the bones along the proximal rows and distal rows:

“Suzie Longs To Pee, Her Corset’s Too Tight”

Fig 41 shows the anterior of the left wrist. The joint between the radius and ulna and the carpal bones is called the **radiocarpal joint**, as the distal end of the radius is the only joint surface that articulates with the carpal bones. There is also a cartilaginous wedge at the distal end of the ulna.

Note:

- The lunate is immediately distal to the radio/ulnar joint
- The capitate distal to the lunate
- The pisiform rides on the triquetral
- The scaphoid can be located just distal to, and deep, to the styloid process of the radius
- On the distal row, the thumb articulates with the trapezium as a saddle joint
- The index finger articulates with the trapezoid
- The middle finger articulates with the capitate
- The ring and little finger articulate with the hamate

Flexor Retinaculum and Carpal Tunnel

The flexor retinaculum (transverse carpal ligament) is stretched across the anterior surface of the carpal bones.

Its attachments are:

- Medially
 - Hamate and pisiform
- Laterally
 - Scaphoid and trapezium

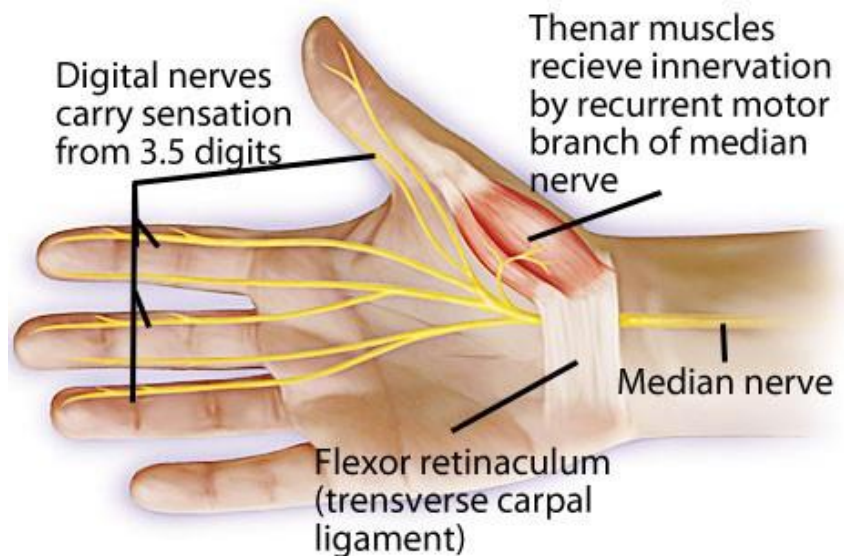


Figure 42 Flexor retinaculum

The flexor retinaculum forms the roof of the carpal tunnel; a passage through which passes:

- All the flexor tendon passing through to the digits
- The median nerve

Its main function is to retain, or hold down, all the flexor tendons as they pass underneath it

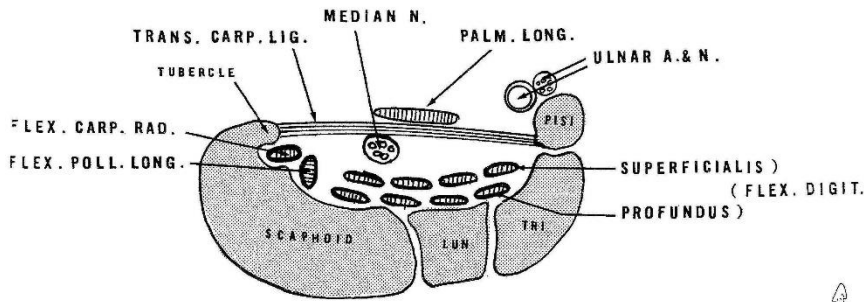
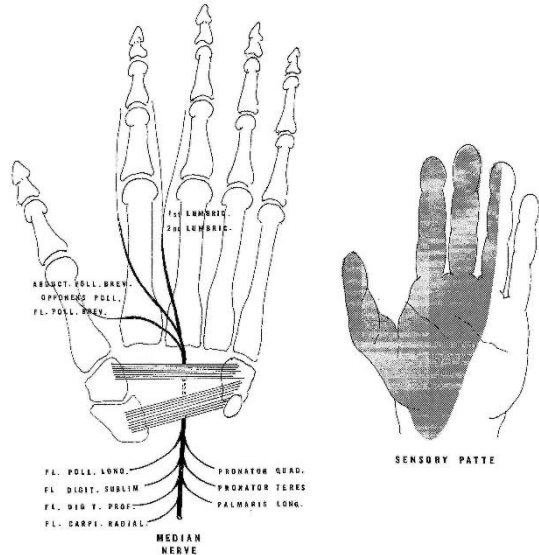


Figure 43 Flexor retinaculum and contents

The median nerve

- Passes through the carpal tunnel
- It supplies
 - The thenar eminence (see later)
 - The skin on the lateral 3 ½ digits

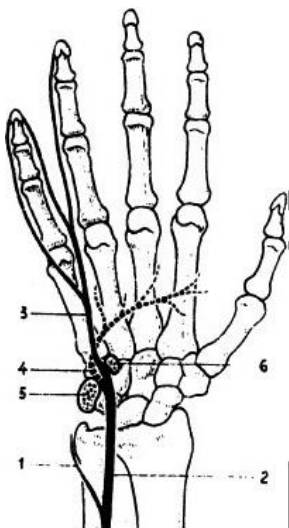
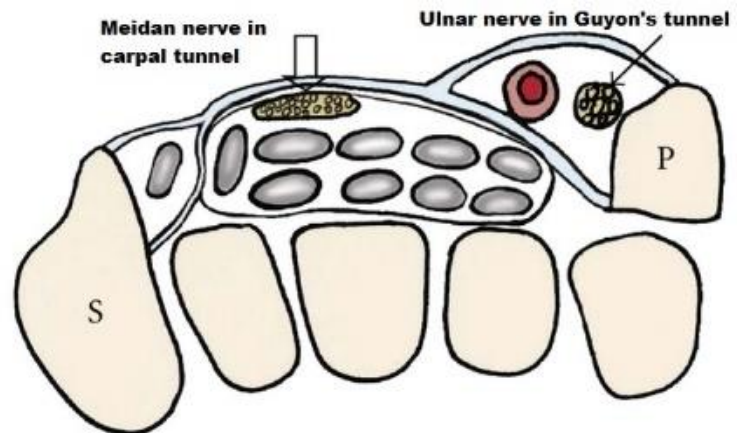
Figure 44 Median nerve distribution in hand



All the tendons passing through here pass through wrapped up in their own synovial tube (to facilitate their movement).

Also, here, the ulnar nerve enters the hand by passing through Guyon's Canal. This is a tight tunnel that is formed between the pisiform and hamate bones and the ligaments that join these bones together (pisohamate ligament).

Figure 45 Ulnar nerve in Guyon's tunnel



Either within or just beyond the canal, the ulnar nerve divides again in to two motor branches which supply some of the muscle in the hand and fingers. These branches are the branch to the hypothenar and the deep motor branch of the ulnar nerve. These innervate the muscles that help move the little finger and thumb respectively.

Figure 46 Ulnar nerve distribution

The Extensor Retinaculum

In a similar way to the flexor retinaculum, it holds down the extensor tendons as they pass underneath it.

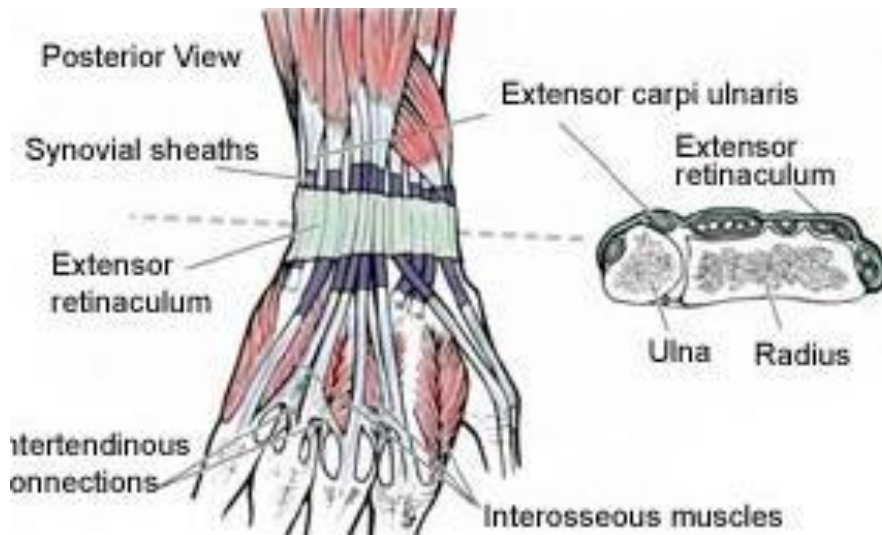


Figure 47 Extensor retinaculum

Note here the synovial sheath, as with the flexor tendons. The main difference here is the webbing effect; the intertendinous connections. This changes the capability of the extension of the fingers.

- The index and little fingers have their own separate muscles, so they are unaffected by these
- The middle finger can extend easily
- The most affected is the ring finger and cannot extend on it own

The Anatomical Snuffbox

The anatomical snuffbox is an anatomical landmark that can be seen as a small concavity when the thumb is fully extended. It can be seen just distal to the extensor retinaculum and between the courses of tendons:

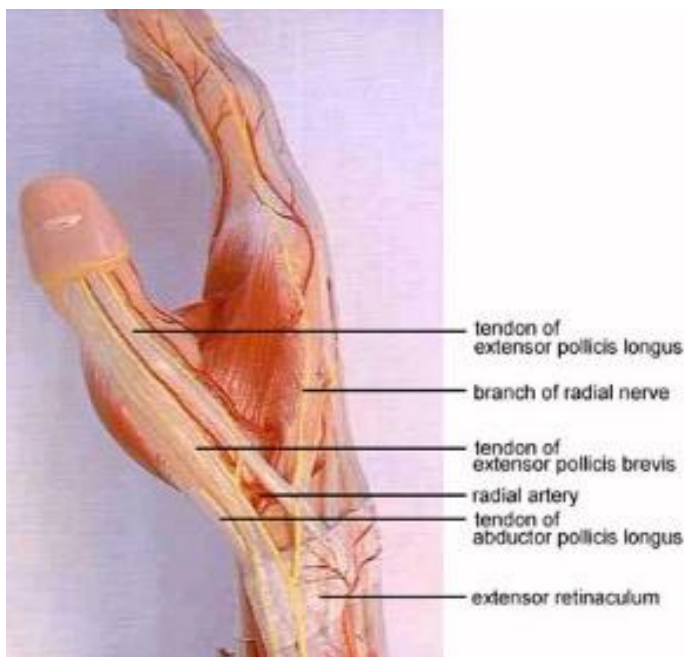


Figure 48 Anatomical snuffbox

Posterior edge:

- Extensor pollicis brevis
- Abductor pollicis longus

Anterior edge

- Extensor pollicis longus

Proximally:

- Styloid process of the radius

The anatomical snuff box is an important landmark in that the scaphoid is at its floor. Pain on palpation here can indicate a fracture

The muscles crossing the wrist have already been covered, but it is good to remind ourselves of the course of the tendons passing through their synovial sheaths.

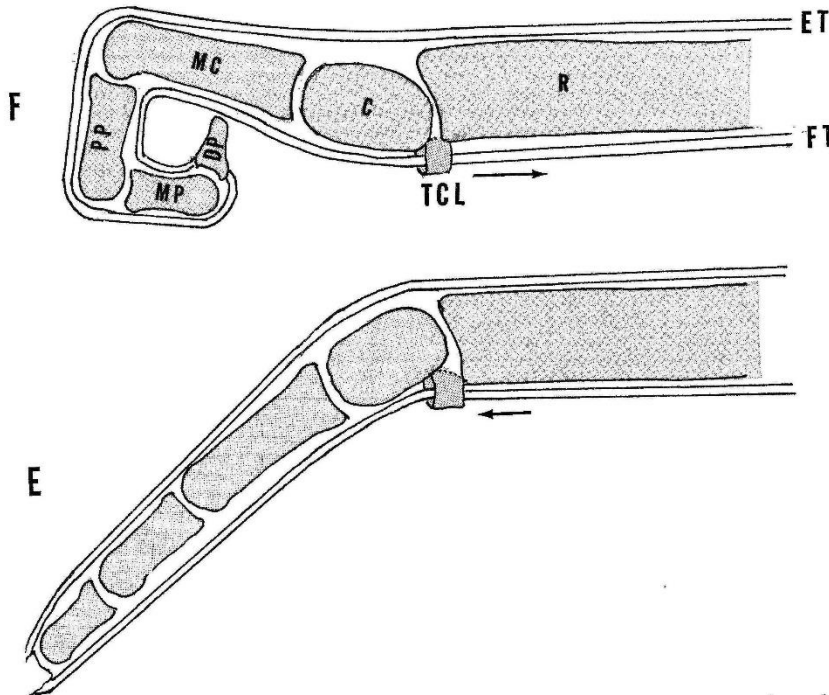


Figure 49 Tendons to fingers

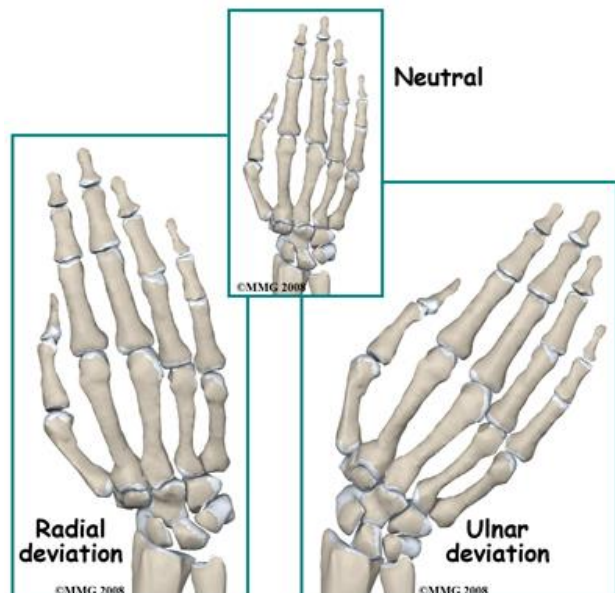
This figure shows the retinacula and the tendon sheaths and how the flexor retinaculum assists with both wrist and finger function. If the fingers are straight, it can help in flexion of the wrist. The grip strength is stronger when the wrist is extended, and is weak in flexion.

Movements of the wrist

The radiocarpal joint is an ellipsoid joint allowing two ranges of movement:

- Flexion and extension
 - Flexion 75° (mainly at midcarpal joint)
 - Extension 70° (mainly at radiocarpal joint)
- Radial and ulnar deviation
 - Radial deviation 20° (mainly at radiocarpal joint)
 - Ulnar deviation 35° (mainly at radiocarpal joint)
- Circumduction
 - A summation of the other four

Figure 50 Radial and ulnar deviation



The Hand Bones

The bones of the hand are

- 5 metacarpals
- 14 phalanges, and of these
 - The fingers have 3 each – proximal, intermediate and distal
 - The thumb only 2 – proximal and distal

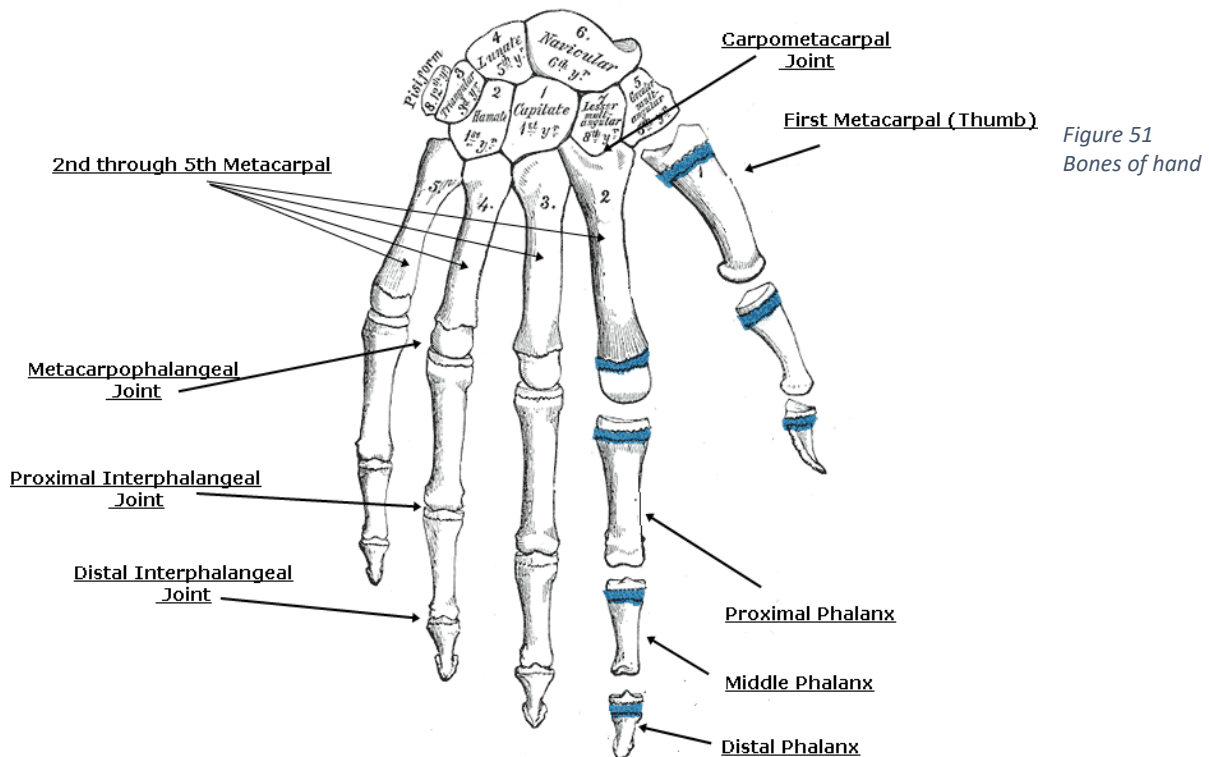


Figure 51
Bones of hand

Joints

Carpometacarpal joints

These are all gliding joints, except for the joint at the base of the thumb, with the trapezium, which is a saddle joint.

Movements

- Away from the palmar surface – **abduction**
- Towards the palmar surface – **adduction**
- Across the palmar surface – **flexion**
- Over towards the little finger – **opposition**

Metacarpophalangeal joints

These are ellipsoidal joints. The rounded heads of the metacarpals articulate with the cups of the proximal phalanges. The palmar aspects of the joint capsules are thickened and strong.

Movements

- Flexion and extension
- Radial and ulnar deviation

Interphalangeal joints

These are hinge joints. There are palmar and collateral ligaments

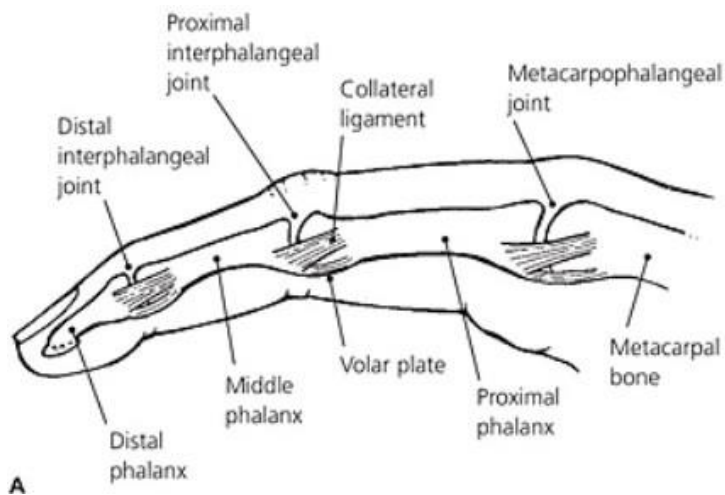


Figure 52 Finger ligaments

Movements – Flexion and extension

Muscles of the Hand – Intrinsic Muscles

The muscles of the hand consist of the:

- **Thenar eminence** – at the base of the thumb, on the palmar side
- **Hypothenar eminence** – at the base of the ulnar side of the palmar side of the hand
- **Intrinsic muscles** – between the metacarpals

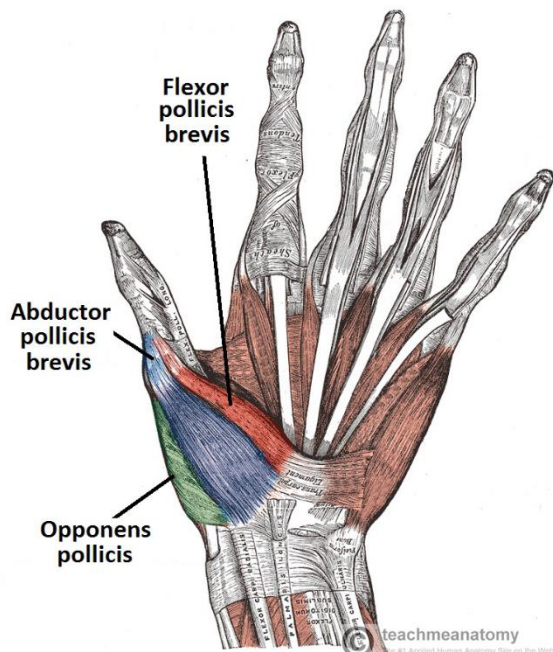


Figure 53 Thenar and hypothenar muscles

The thenar and hypothenar muscles move the thumb and little fingers, respectively

Thenar eminence:

- **Abductor pollicis brevis**
 - Moves thumb away from palmar surface
- **Flexor pollicis brevis**
 - Flexes thumb
- **Opponens pollicis**
 - Move thumb across to little finger (as part of grip)

Hypothenar eminence

- **Abductor digiti minimi**
 - Moves little finger towards ulnar side
- **Flexor digiti brevis**
 - Flexes little finger
- **Opponens digiti minimi**
 - Moves little finger across palm to thumb

The intrinsic muscles of the hand are difficult to visualise, but are easier to be seen in terms of their function

Dorsal interossei

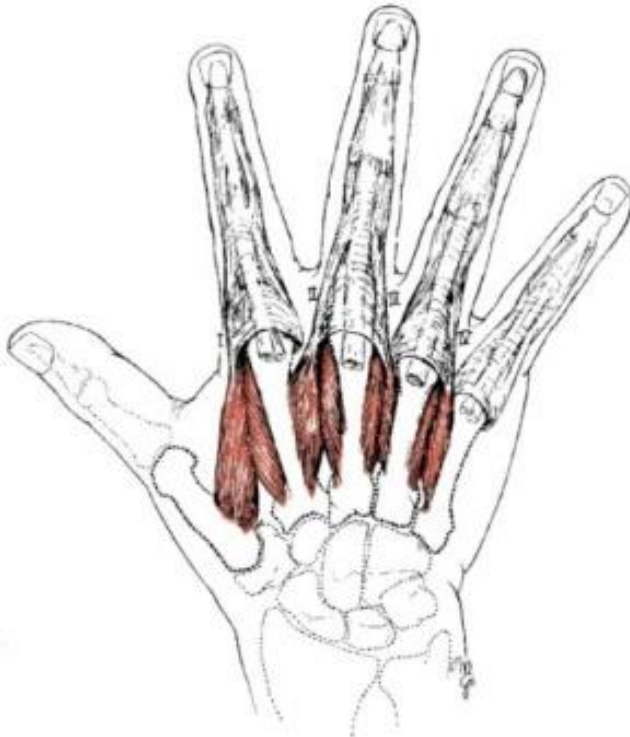


Figure 54 Dorsal interossei

These muscles abduct the fingers - away from the midline of the hand

Palmar interossei

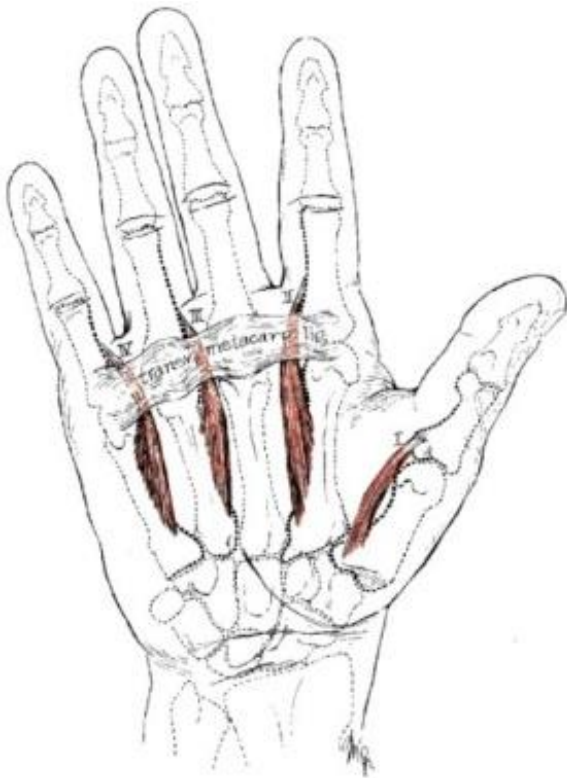

Figure 55 Palmar interossei

These muscles adduct the fingers – towards the midline of the hand

Lumbricals

These muscles flex the fingers at the metacarpophalangeal joint

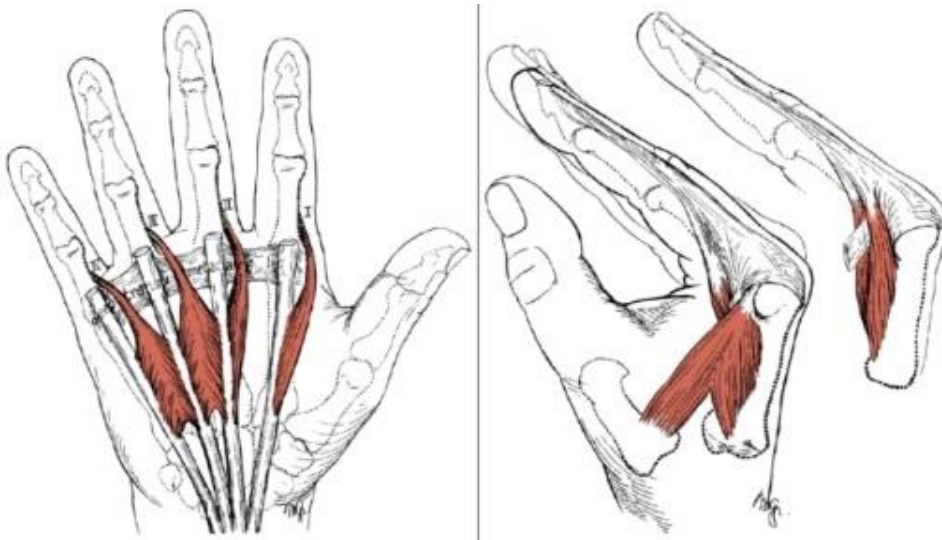


Figure 56 Lumbricals

Injuries to the Wrist

Fractures – Distal Radius

Colles' Fracture

This is a fracture of the distal end of the radius, usually with a posterior displacement. It usually happens with a fall on an outstretched arm. It can occur most frequently in those suffering from osteoporosis.

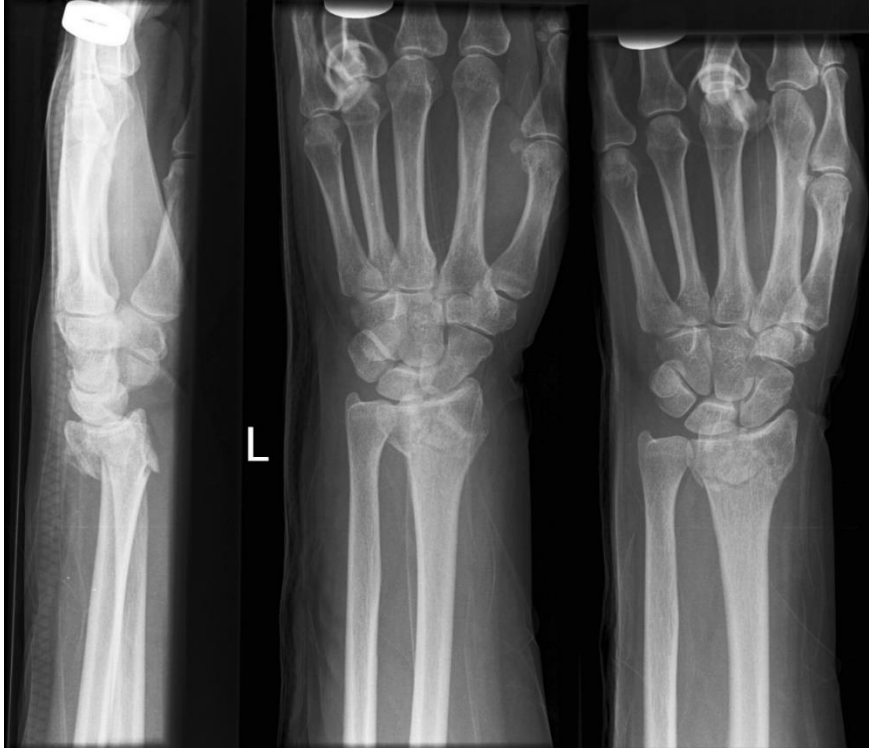
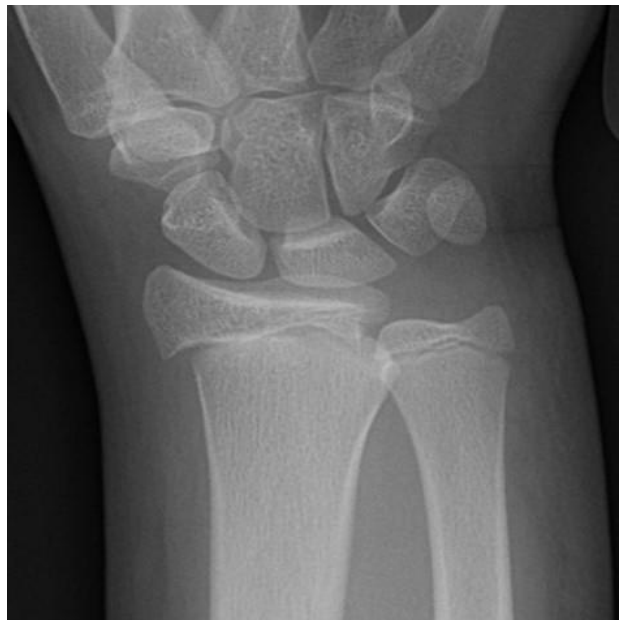
Figure 57 Colles' fracture X-ray

Salter-Harris fracture

A **Salter–Harris fracture** is a fracture that involves the epiphyseal plate or growth plate of a bone. It is a common injury found in children, occurring in 15% of childhood long bone fractures.

Figure 58 Salter-Harris fracture



Smith's fracture

Fall on outstretched hand with wrist in flexed position and supinated. A flexion and compression fracture of the lower end of the radius, with forward displacement of the lower fragment.

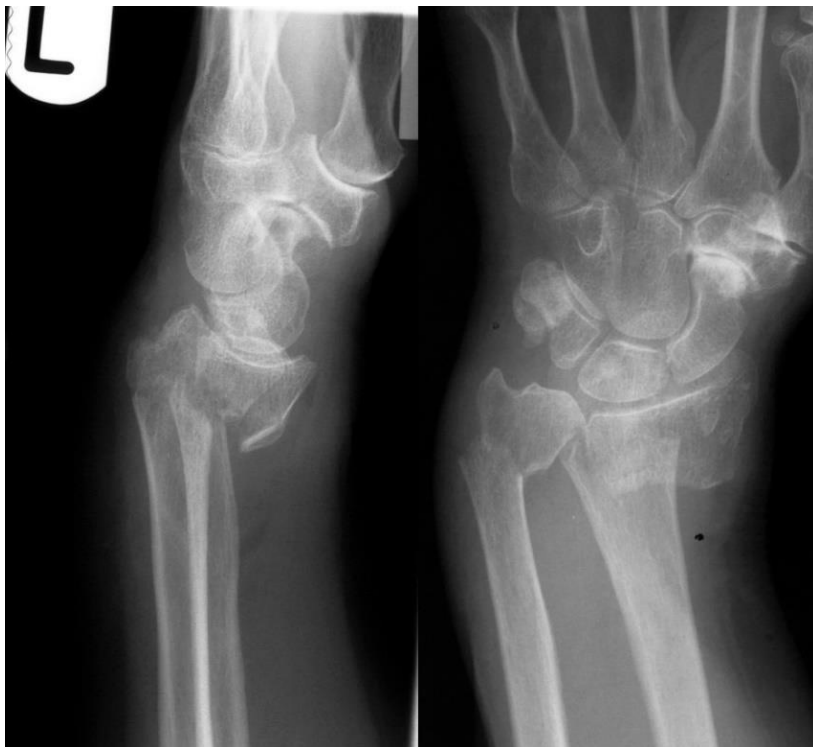

Figure 59 Smith's fracture

Intra-articular Fractures:

Die Punch Fracture: Lunate impaction injury into distal radius.

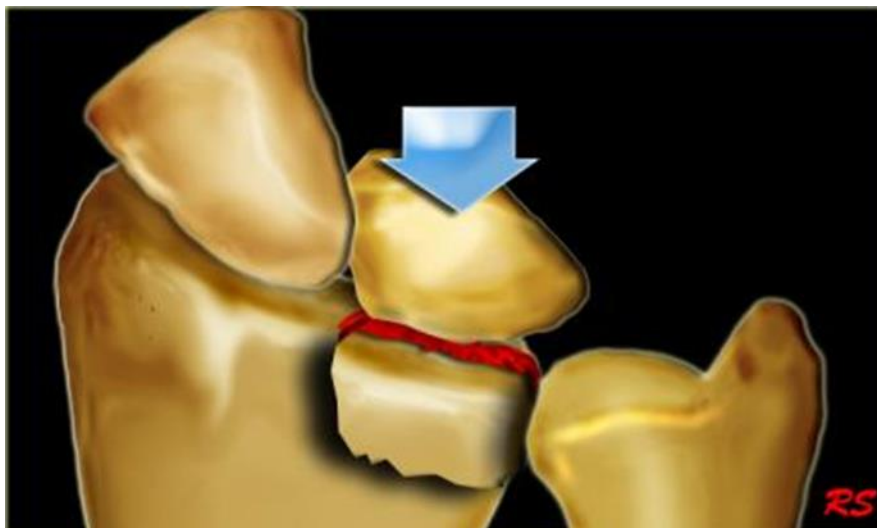

Figure 60 Die Punch Fracture

Barton's Fracture

High energy shear forces result in intra-articular fracture; carpal bones move with sheared radial head fragment through line of joint

Volar Barton's: Wrist in flexion

Dorsal Barton's: Wrist in extension

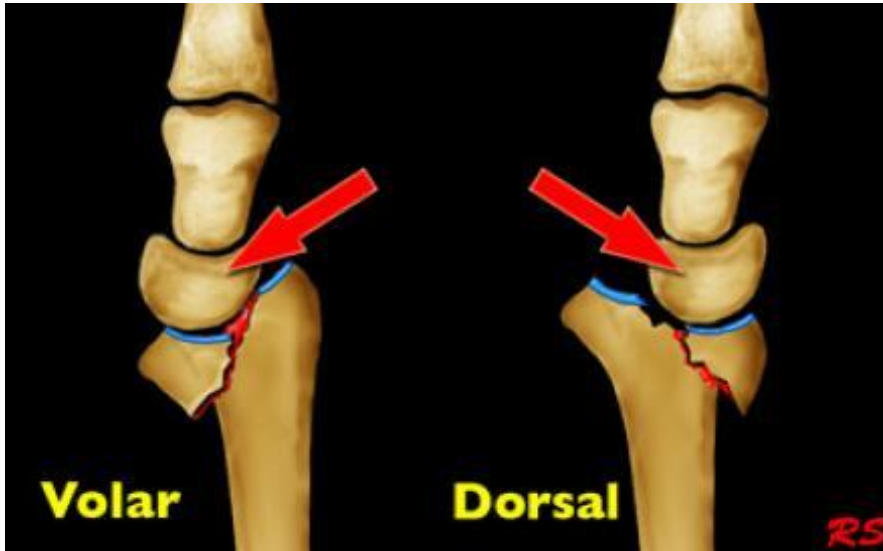


Figure 61 Barton Fracture

Chauffeur Fractures

Also known as Backfire Fractures/Hutchinson Fractures: Fractures of the radial styloid.

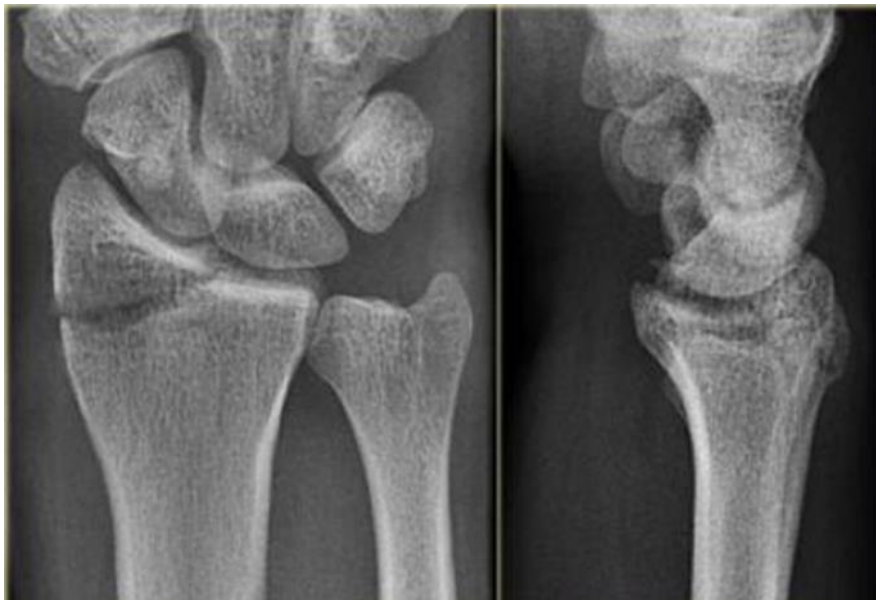

Figure 62 Chauffeur Fracture

Scaphoid fracture

The scaphoid is a small, crescent shaped, bone on the lateral side of the wrist, just distal to the styloid process of the radius; it frequently only received a blood supply from its distal end.

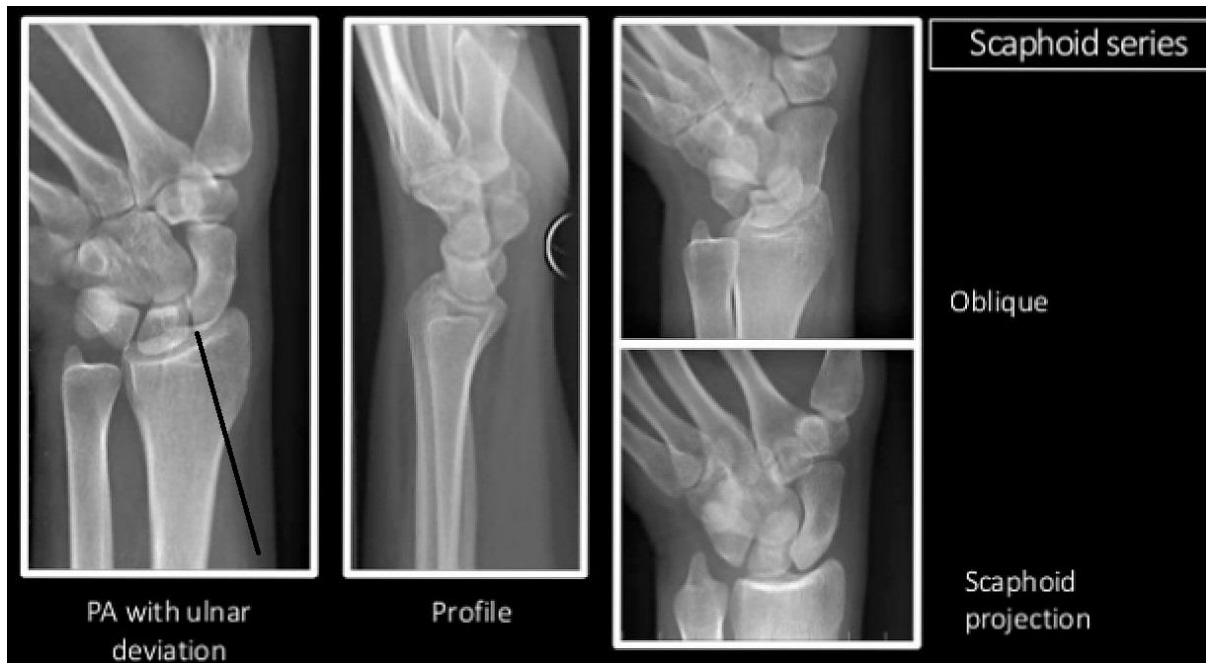

Figure 63 Scaphoid fracture

This X-ray shows a scaphoid fracture (indicated by the line), but as with the way with X-rays, you need to see through the line of the fracture to actually see it. Here sometimes 4 views are taken from different angles to be sure.

Because of the arrangement of the blood supply it needs to be reduced and immobilised quickly, else the area of the bone farthest from the fracture may die, resulting in avascular necrosis. This will require surgery and may predispose to osteoarthritis later in life.

It can result from a fall on an outstretched arm

Symptoms

The person may present with pain and swelling, though this may be confused with a simple sprain. As with all the wrist bones, they share a joint capsule, so it can be tested via palpation in the anatomical snuff box. Any pain precipitated here and an X-ray is **obligatory**.

Treatment

Immobilisation of the wrist and homeopathic symphytum (Comfrey [bone knit])

Bennett's fracture

Axial load along metacarpal in a partially flexed thumb as an intra-articular fracture-dislocation of the base of the first metacarpal

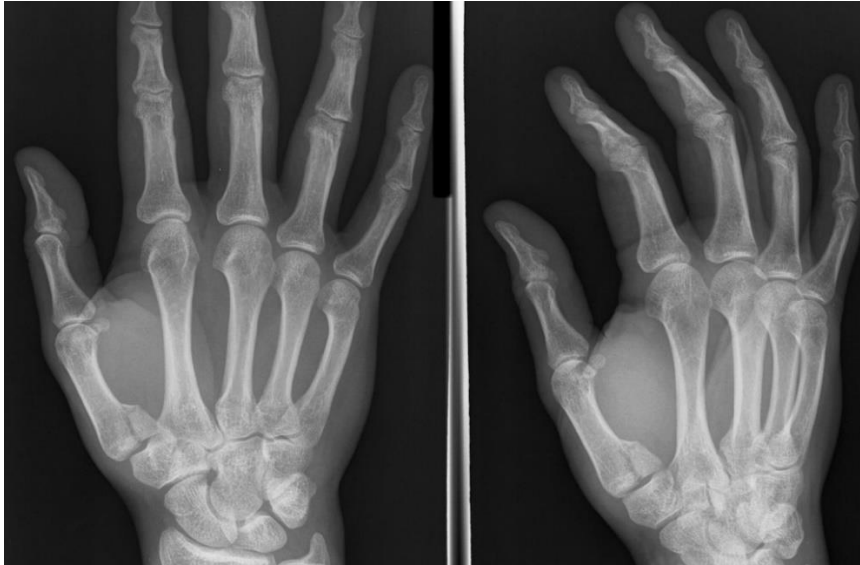

Figure 64 Bennett's fracture

Galeazzi fracture

Fracture of the shaft of radius (most commonly at the junction of the middle and distal thirds) with dislocation of distal radioulnar joint

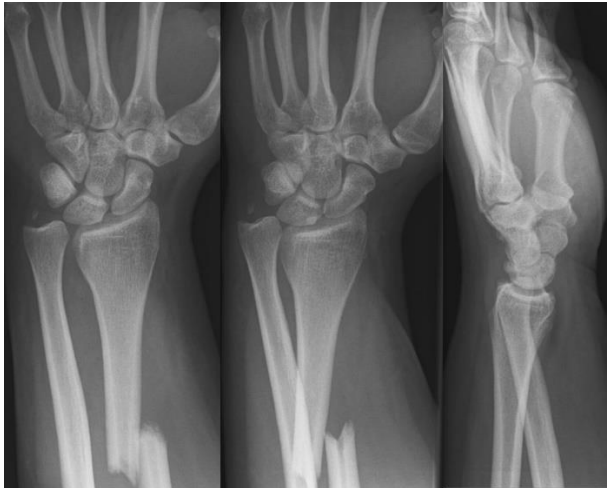


Figure 65 Galeazzi Fracture

Hamate fracture

The hamate is a bone of the distal row in the wrist and has an apparent 'hook' onto which the flexor retinaculum attaches. This injury can occur during a golf swing when the player hits the ground

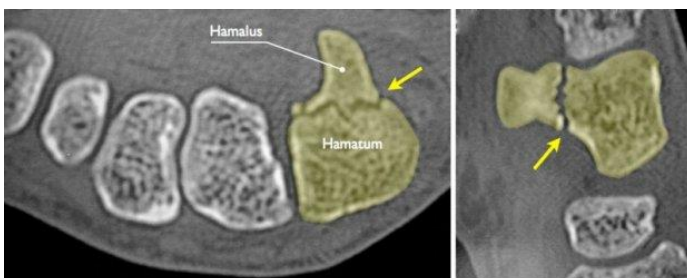


Figure 66 Hamate fracture

Dislocated wrist

A dislocation is when a joint is taken outside its normal physiological range of movement. With this there will always be capsular sprain, or damage; perhaps even bleeding. As capsular structures are ligamentous in nature, they can be slow healing.

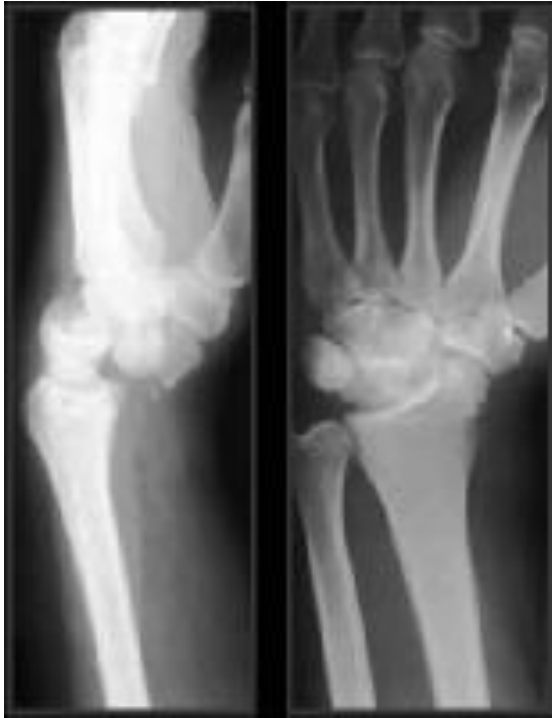

Figure 67 Dislocated wrist

It can be gross, as shown here in fig 56, or more specific as in Fig 58.

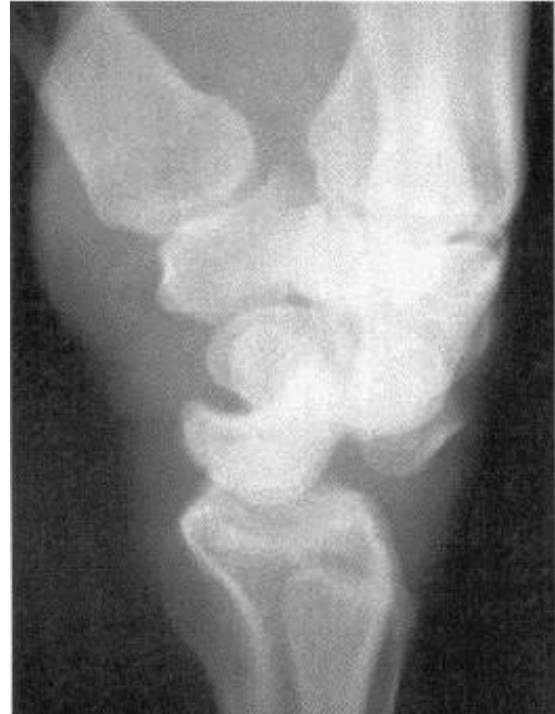

Figure 68 Dislocation of lunate bone

Lunate dislocation can occur with weightlifting and the 'clean and jerk'. Anterior dislocation of the lunate can cause median nerve compression with pins and needle into the hand.

Kienböck Disease

The changes seen in Kienböck disease are due to avascular necrosis of the lunate bone. It has an insidious onset, frequently without known prior injury. Patients present with wrist pain, decreased motion and have sclerosis of the lunate. Although pathogenesis is not conclusively established, transverse fractures, numerous compression fractures secondary to repeated compression strain and lunate dislocation, all leading to avascular necrosis in "at risk" individuals, have been proposed explanations.

The age distribution for Kienböck disease depends on gender. The condition is most common within the dominant wrist of young adult men where it appears to be due to repeated loading of the lunate. In women, Kienböck disease typically occurs in middle age and is equally divided between the dominant and non-dominant wrist¹.

There is a significant association between *negative ulnar variance* and Kienböck disease, although many people with negative ulnar variance do not have the condition. A causal association is difficult to prove, however the effectiveness of decompressive procedures such as radial shortening or ulnar lengthening in relieving pain and preventing further collapse of the lunate is supportive. Overall, negative ulnar variance is present as a predisposing factor in around 75% of cases of Kienböck disease.

The pathologic changes are equivalent to those of avascular necrosis of other bones. There is disruption of critical blood supply leading to bone infarction, central necrosis and surrounding hyperaemia. Microfractures ensue resulting in flattening and deformity of the bone surface.

In 70% of lunates there is vascular supply multiple vessels either volarly or dorsally. In the remaining 30% only a single vessel is present volarly and dorsally, which may explain some of the vulnerability of the lunate to avascular necrosis.

Pathology

Sclerosis and flattening of the lunate. When flattening is marked, there is rotation of the scaphoid which further adds to the stress on the lunate. Fragmentation of the lunate and secondary degenerative disease may develop later.

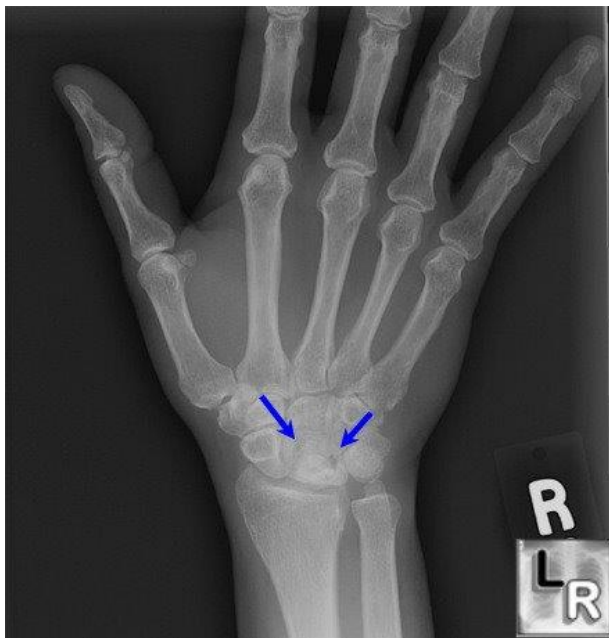

Figure 69 Kienböck disease

Four stages have been noted:

- Stage I - Normal radiograph
- Stage II - Sclerosis of lunate with possible decrease of lunate height on radial side only
- Stage IIIa - Lunate collapse, no scaphoid rotation
- Stage IIIb - Lunate collapse, fixed scaphoid rotation
- Stage IV - Degenerative changes around the lunate

It usually occurs in young adults (15-40 years of age) and is unilateral.

Symptoms

- Pain – up forearm and with dorsiflexion of the middle finger
- Stiffness and swelling over the lunate
- As the lunate collapses there will be reduced range of movement and a weak grip

Treatment

- If caught early, stop the activity causing the compression
 - Comfrey to assist bone healing
- If caught late, it may require surgery

Treatment and prognosis

Conservative management with rest, non-steroidal anti-inflammatory drugs and immobilisation in mild cases is often very effective. Radial shortening to correct negative ulnar variance is the most common surgical therapy with good results. Other operative procedures include ulnar lengthening, revascularisation, lunate excision with or without

prosthetic replacement and inter-carpal fusion. Proximal row carpectomy is used as a salvage procedure in refractory cases

Ulnar impaction syndrome

Ulnar impaction syndrome, also known as **ulnar abutment** or **ulnocarpal loading**, is a degenerative wrist condition caused by the ulnar head impacting upon the ulnar-sided carpus with the injury to the *triangular fibrocartilage complex* (TFCC).

Triangular fibrocartilage complex

In 1981, Palmer and Werner used the term **triangular fibrocartilage complex** (TFCC) to describe the set of related structures at the distal ulnar aspect of the wrist. The TFCC is between the distal radioulnar joint (DRUJ) and the radiocarpal joint. It is comprised of:

- A central articular disc
- Dorsal and volar radioulnar ligaments
- Meniscal homologue
- Ulnocarpal ligaments
- Extensor carpi ulnaris sheath.

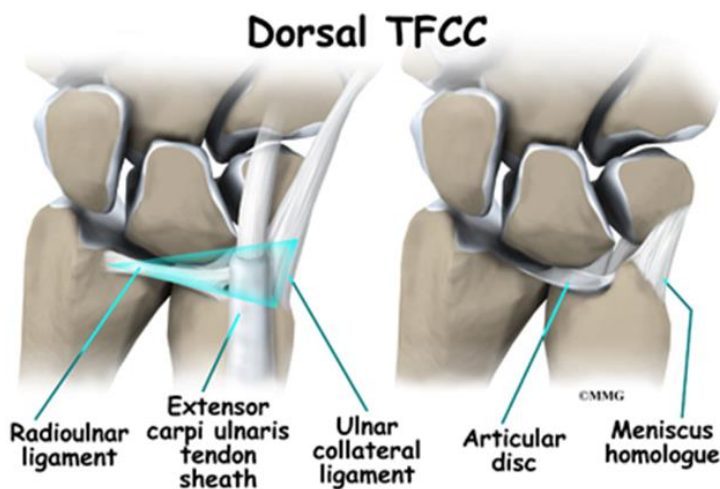


Figure 70 TFCC A-P view

The primary structure is the triangular fibrocartilage or meniscal disc that is a relatively avascular disc-like structure that provides a cushion effect between the distal articular surface of the ulna and the proximal carpal row, primarily the triquetrum.

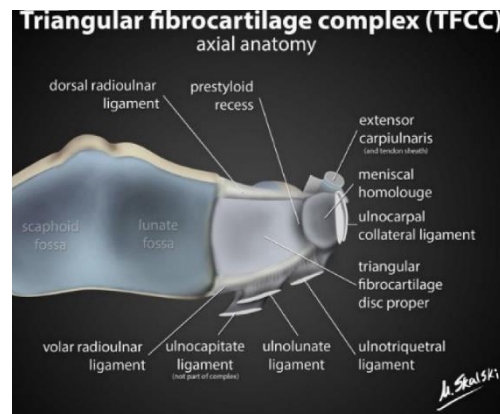
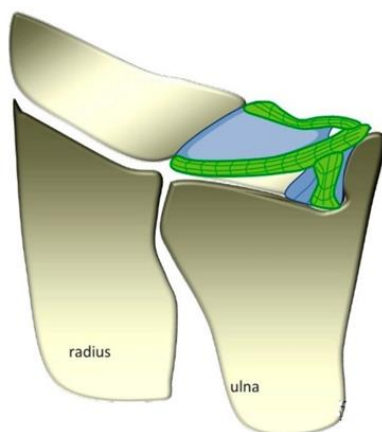


Figure 71 Triangular Fibrocartilage Complex - Axial view

There are attachments on the ulnar border of the radius and the base of the ulnar styloid. The articular disc is composed of fibrocartilage; its base is attached to the radius along the distal edge of the sigmoid notch. Along the dorsal margin of the articular disc is the dorsal radioulnar ligament, which connects the dorsal aspect of the sigmoid notch of the radius to the styloid process of the ulna. Extending from the dorsal radioulnar ligament in a distal direction are fibers called the extensor carpi ulnaris tendon sheath, which variably extends to the base of the fifth metacarpal. Along the palmar edge of the articular disc is the palmar radioulnar ligament, which connects the palmar edge of the sigmoid notch to the area at the base of the ulnar styloid process, called the fovea.

The disc is a biconcave structure with a radial attachment that blends with the articular cartilage of the radius. The ulnar attachment lies at the base of the ulnar styloid. The anterior and posterior thickenings of the TFCC are confluent with the anterior and posterior radioulnar capsule and are called the palmar and dorsal radioulnar ligaments. These structures develop tension as the forearm is pronated and supinated and provide the primary stabilization to the DRUJ.

The functions of the TFCC are:

- Help suspend distal radius and ulnar carpus from distal ulna
- Act as major ligamentous stabiliser of distal radioulnar joint
- Provide continuous gliding surface across entire distal face of radius and ulna
- Allow for smooth flexion/extension and translational movements of wrist
- Act as shock absorber for forces transmitted over ulnocarpal axis

The TFCC must be simultaneously robust and flexible. It must have the strength to transmit 20% of the load of the carpus to the ulna and to stabilize the DRUJ and ulnar carpus in conjunction with the bony architecture of the sigmoid notch. It must also be supple enough to accommodate the significant, complex motion that occurs during forearm rotation. The motion of the DRUJ is a combination of approximately 150 degrees of rotation and sliding. This occurs because the radius of curvature is 50% larger on the radial side of the DRUJ (15 versus 10 mm). The axis of rotation passes through the fovea of the ulnar head, which is a major attachment site for the TFCC. The central portion of the TFCC is avascular; only the outer 10–15% of the periphery has a reliable vascular supply.

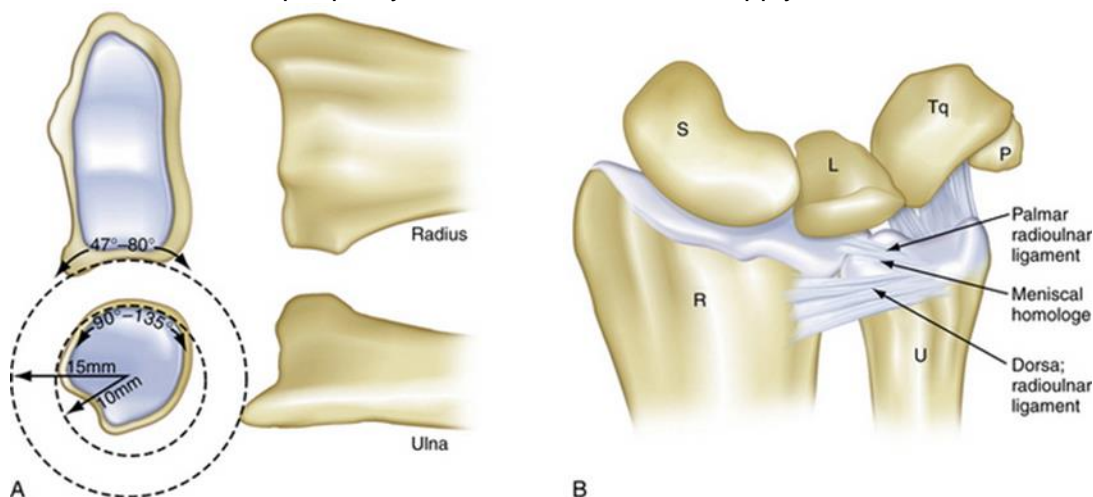


Figure 72 Distal ends of radius and ulna: joints and ligaments

Much like the menisci in the knee, vascular studies have demonstrated poor central vascularity, whereas the peripheral 15% to 20% has the arterial inflow required for healing.

In addition, there is no vascular contribution from the radial base of the TFCC. Thus, central defects or tears tend to have difficulty healing and more peripheral injuries heal at a much higher rate.

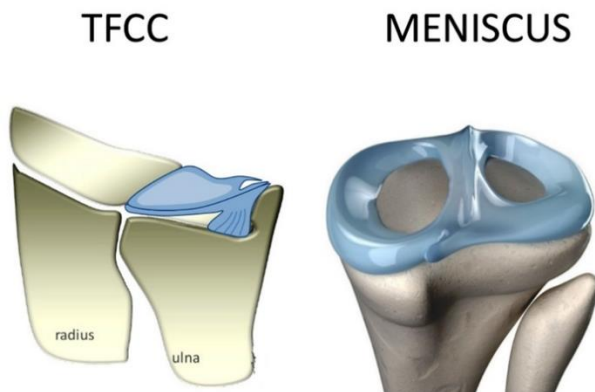


Figure 73 TFCC and Meniscus

Degeneration of the TFCC begins to occur as part of the natural aging process in the third decade. This degenerative process predisposes the TFCC to traumatic injury.

- Falls onto fully pronated and hyperextended wrist
- Water-skiing and horseback riding dragging injuries causing critical distraction forces to be applied to volar forearm and wrist
- Power drill injuries in which the drill bit binds and the drill handle forcibly rotates the wrist rather than the drill bit
- Distal radius fractures
- Degenerative changes

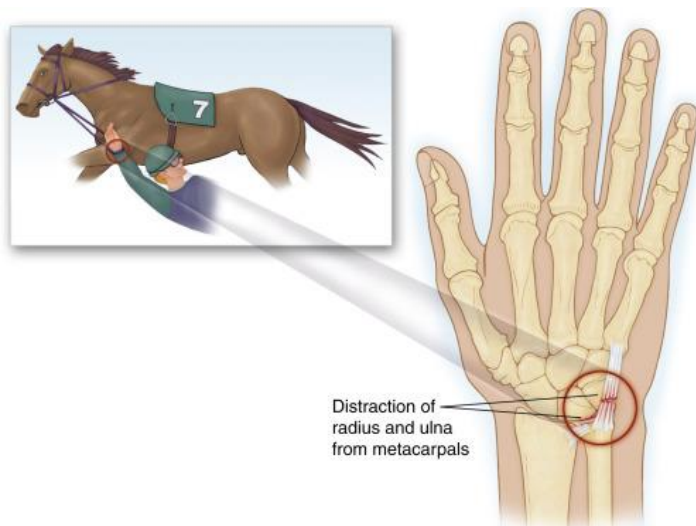


Figure 74 Traction Injury to TFCC

Injuries to the TFCC and DRUJ are quite common in athletes. Both direct, acute trauma and chronic, repetitive trauma can lead to tearing of the complex. Palmer et al. created a well-known classification of these injuries, dividing them into traumatic and degenerative groups; the traumatic group is further divided by location of the tear. Traumatic tears are most commonly located centrally or peripherally, and the latter may lead to DRUJ instability.

Acute trauma is usually the result of a fall onto an outstretched arm or a direct impact. Athletes competing in sports such as gymnastics, golf, and ice hockey commonly experience ulnar sided wrist pain and TFCC injury.

Patients often present with complaints of ulnar sided wrist pain. On examination, they have tenderness to palpation over the TFCC region located on the ulnar wrist between the pisiform and the ulnar styloid. They may have pain or difficulty lifting heavy objects in a supinated position. The differential diagnosis for patients with these complaints includes lunotriquetral pathology, ulnocarpal impaction, pisotriquetral arthrosis, and ECU or FCU tendonitis. DRUJ instability can be associated with TFCC injury.

Epidemiology of Ulnar Impaction Syndrome

Ulnar impaction syndrome most commonly presents in middle-aged patients. The majority of cases occur in association with positive ulnar variance or increased dorsal tilt of the distal radius, which may be congenital or due to a previous fracture, premature growth plate closure or radial head resection (such as may follow an *Essex-Lopresti fracture-dislocation*). Ulnar impaction syndrome is rare in the absence of such anatomic predispositions but can occur if there is excessive repeated loading of the ulnar-carpus in daily activity.

Clinical presentation

Patients present with chronic or subacute ulnar-sided wrist pain exacerbated by activity. There is often associated swelling and limitation of forearm and wrist movement. Anything that results in a relative increase in ulnar variance such as firm grip, pronation and ulnar deviation of the wrist, can exacerbate the symptoms.

Pathology

As the name suggests, ulnar impaction syndrome involves impaction of the distal ulnar upon the ulnar-sided carpal bones, particularly the lunate. This results in a continuum of pathologic changes which are represented in the class II subsection of the *Palmer classification of TFCC lesions*.

- IIA TFC complex wear
- IIB TFC complex wear, lunate or ulnar chondromalacia
- IIC TFC complex perforation, lunate or ulnar chondromalacia
- IID TFC complex perforation, lunate or ulnar chondromalacia, lunotriquetral ligament perforation
- IIE TFC complex perforation, lunate or ulnar chondromalacia, lunotriquetral ligament perforation, ulnocarpal osteoarthritis

Radiographic features

Imaging findings of ulnar impaction may precede the onset of symptoms. Recognising the distribution pattern (ulnar, lunate, triquetral) is the key to making the diagnosis.

Plain radiograph

Plain radiographs can appear normal in early disease. General features include:

- presence of a predisposing factor
 - positive ulnar variance
 - previous distal radial fracture with shortening or dorsal tilt
 - distal radial resection
 - Madelung deformity
- subchondral sclerosis and cysts in specific ulnar impaction distribution
 - distal ulnar

- proximal ulnar aspect of lunate
- radial aspect of triquetrum
- ulnocarpal osteoarthritis in more advanced disease

MRI

MR imaging is the investigation of choice in both detection of early disease and characterisation of more advanced disease. Can demonstrate the bone, cartilage and ligamentous features of the syndrome.³

Location of bone signal changes⁴

- ulnar side of proximal lunate ~ 90%
- radial side of proximal triquetrum ~ 40%
- distal ulnar ~ 10%

Types of bone signal change

- subchondral sclerosis (low T1 and T2) most common in lunate
- bone oedema (high T2, low-intermediate T1)
- subchondral cysts (round T2 hyperintensities)

Cartilage and ligamentous changes

- chondromalacia of distal ulnar cartilage (altered signal)
- central TFCC signal increase often with tear (T2 hyperintense fluid)
- lunatotriquetrum ligament tear (T2 hyperintense fluid) with proximal arc offset

Differential diagnosis of TFCC injuries

- Tendinopathy of the ECU
- Ulnar styloid fracture
- Distal radius fracture
- DRUJ Arthritis
- Pisiform bone fractures
- Hamate bone fractures
- Carpal instability
- Midcarpal instability
- Hypothenar hammer syndrome (ulnar artery thrombosis)

Treatment and prognosis

Treatment varies depending on the amount of ulnar variance, the Palmer lesion class, the contour of the distal ulnar and the presence of lunotriquetrum instability.

Palmer class IIA and IIB lesions (no TFC perforation) are managed with open wafer procedure (surgical resection of the distal 2–3 mm of the dome of the ulnar head) or formal ulnar shortening (excision of a 2-3 mm slice of the ulnar shaft followed by fixation).

When the TFC is perforated (Palmer class IIC and IID lesions), the head of the ulna can be burred down with the help of arthroscopic instrumentation (arthroscopic wafer procedure). This procedure is minimally invasive, highly effective, and allows rapid return to normal activities.

Class IIE lesions are managed with salvage procedures such as complete or partial ulnar head resection (Darrach procedure) or arthrodesis of the distal radioulnar joint with distal ulnar pseudoarthrosis (Sauve-Kapandji procedure).

Carpal tunnel Syndrome

As has been described above, the carpal tunnel is a narrow fibro-osseous sheath on the front of the wrist, through which passes:

- Flexor pollicis longus tendon
- Four flexor digitorum longus tendons
- Four flexor digitorum superficialis tendons
- Flexor carpi radialis longus
- The median nerve

Carpal tunnel syndrome occurs when the median nerve is compressed within these anatomical structures. There are three categories:

- Increased volume of the contents of the carpal tunnel
- Enlargement of the median nerve
- Decreased cross-section of the area within the tunnel

Of these, the increased volume of the contents of the tunnel are considered to cause tendinitis and tenosynovitis in most symptomatic patients. Enlargement of the median nerve is rare, as is decreased cross-sectional area without the presence of rheumatoid arthritis.

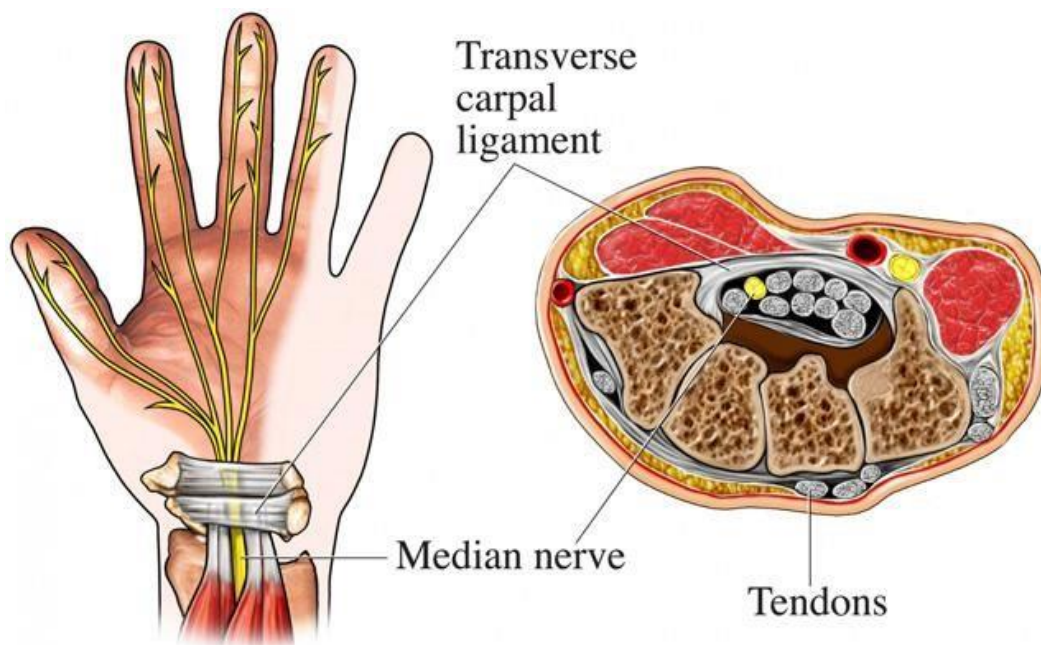


Figure 75 Carpal tunnel syndrome

Surgical interventions and other investigations of carpal tunnel syndrome have shown thickened and oedematous synovial sheaths of the enclosed tendons. Most people have a mild tenosynovitis of the tendons within the tunnel, but to a lesser extent than people who have carpal tunnel syndrome.

The main flexor tendons are the main factors causing compression of the median nerve, causing the primary locus of impairment and disability. Low grade peripheral nerve compression, epineural (on the nerve) blood flow, axonal transport (flow from transport systems within the nerve axons: orthograde – towards the muscles, retrograde – away from

the muscles), and endoneural fluid pressure is increased. All this creates a situation of a space occupying lesion, compressing the nerve and impairing neural function.

Symptoms

Patients with early carpal tunnel syndrome have pins and needles and tingling in the distribution of the median nerve: thumb, index, middle fingers, lateral half of the ring finger and lateral palm. If there is significant median nerve entrapment, the opposition (of thumb against little finger) test will be positive.

On examination

The patient will demonstrate a positive:

Tinel's test

- Rest the affected hand palm up in your hand, such that the hand falls into extension
- Tap the anterior of the wrist, on the flexor retinaculum
- An increased of perceived symptoms is a positive test

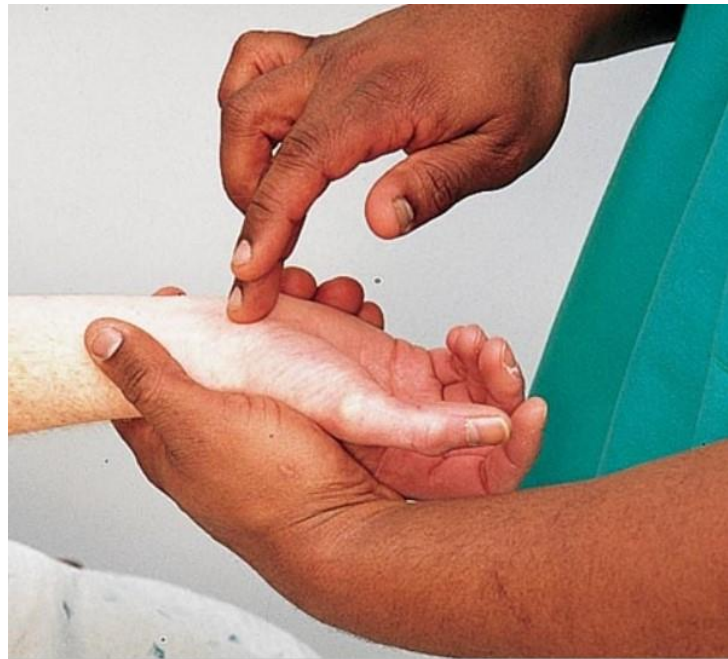

Figure 76 Tinel's test

Phalen's Test

- The patient is asked to hold their wrist in complete and forced flexion (pushing the dorsal surfaces of both hands together) for 30–60 seconds.
 - The lumbricals attach in part to the flexor digitorum profundus tendons. As the wrist flexes, the flexor digitorum profundus contracts in a proximal direction, drawing the lumbricals along with it.
 - In some individuals, the lumbricals can be "dragged" into the carpal tunnel with flexor digitorum profundus contraction.
- As such, Phalen's manoeuvre can moderately increase the pressure in the carpal tunnel via this mass effect, pinching the median nerve between the proximal edge of the transverse carpal ligament and the anterior border of the distal end of the radius.
- Because not all individuals will draw the lumbricals into the carpal tunnel with this manoeuvre, this test cannot be perfectly sensitive or specific for carpal tunnel syndrome



Figure 77 Phalen's test

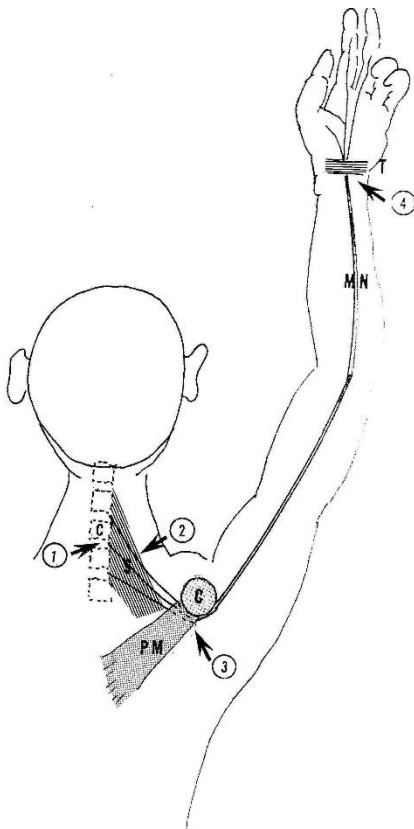


Figure 78 Median nerve course into arm

Fig 78 shows the course of the median through the axilla. It:

- Emerges from its roots: C5, 6, 7, 8 and T1
- Passes between the scalene muscles at the side of the neck
- Passes under pectoralis minor
- Passes through pronator teres
- Under the flexor retinaculum

Treatment for carpal tunnel syndrome may just require local treatment, or giving the body attention elsewhere, as per the diagram in fig 63

In the wrist, it will require general mobilisation, including:

- Biscuit breaking
- Torsion
- Shearing
- Traction and individual bone via 'figure of eight'
- Ultrasound may be of help in resolution of inflammation

Remember that the bulk of the structures in the carpal tunnel are avascular, so swelling here may be the result of a chronic process (i.e. more than 6 months), so resolution may be slow as well. Surgery is sometimes recommended, involving splitting the fascia around the tendons and nerves. NSAI's can be effective, even topical ones.

Tenosynovitis

The term tenosynovitis suggests inflammation of the tendons and synovial sheaths around the tendons in the carpal tunnels and hand, through to the fingers. It is generally accepted that this is a repetitive strain injury brought about by repetitive traumata. Visible thickening has been reported by some and denied by others. Researchers who have found inflammation have noted that the median nerve is also affected. The question asked by some has been to whether the oedema is actually inflammatory; this is asked as inflammatory cells have been found in fewer than 7% of patients with oedema.

Mechanics of injury

Repetitive hand activity, most commonly of small amplitude being an important factor. For example, take an office worker. Once the duties and activities of a secretary would be varied: typing, carriage return, feeding in new pages, filing, stapling etc. with the advent of word processors and computers, the person does not have to move from the desk. Typing is an activity that occurs with very small amplitude of movement of fingers and wrist movements. Filing is pressing 'save' and printing requires pressing one or two keys. Occupational factors that need to be taken into consideration by the practitioner are:

- Repetitive activities
- Computer activities
- Grip force
- Pinch force
- Palm pressure
- Opposition strength
- Vibration
- Glove use
- Exposure to cold
- Intensity of work conditions and stress

The end result of all this is that, instead of the tendons getting variations in range of movement and activity, the tendons only traverse small ranges of movement – but often. The muscles of these tendons are not working over a big arc of movement and hence not being stretched on a regular basis. Because of all this, the fascial structures around the muscles begin to shorten and thicken. The muscles still work but with reduced ranges of movement. Stiffness and pain will result.

Symptoms

Pain and stiffness in the forearm, wrists and palms are the main symptoms; some so severe they cannot move at all. There may also be paraesthesia into the fingers, especially the middle one. Positive tests may be found if Tinel's and Phalen's test are performed.

Treatment

Treatment is similar to that of carpal tunnel syndrome. Emphasis should be put on changing the nature of the activity, even by prescribing mobility exercises of the arms and shoulders. All exercises should be of a gentle nature to encourage, rather than force, mobility of tissues. This can help the patient, if only to take responsibility for their own condition, even if they experience in the early days of the exercises. Tension patterns can be curious things; the person can encounter only tension barriers with exercises, but if any degree of inflammation is present, they will experience definitive pain barriers. This can be a discouraging factor in doing the exercises in the first place.

Some authorities advocate splinting the joint at night, or when it is not being used. This approach is questionable. Just because it 'hurts' doesn't mean immobilising the joint will help the problem. Splinting may give a short term relief but will also cause chronic restriction and stiffness as the joint is not being used. This may be supported by the data that only 20% are symptom free after one year – too few and too slow!

Steroid injection can be used to reduce symptoms. These have the effect of masking the symptoms. They only help the body in the place it is in; it doesn't make it better.

De Quervain's Disease

De Quervain's disease is another type of RSI. It is a tenosynovitis (aka tenovaginitis) of the thumb muscle tendons on their course past the styloid process of the radial head.

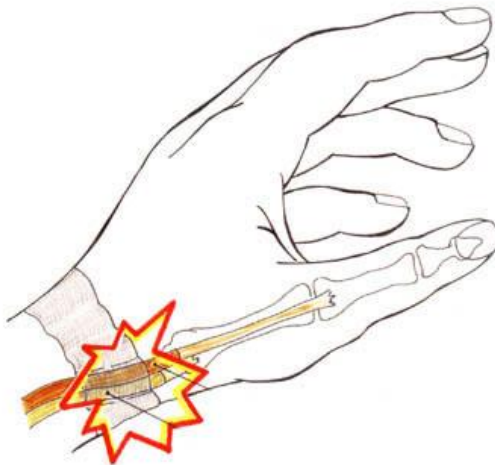


Figure 79 Location of De Quervain's disease

This condition affects the 1.5-inch-long synovial sheath around the tendons of:

- Abductor pollicis longus
- Extensor pollicis brevis

Symptoms

Pain and oedema over the radial styloid process. This is particularly evident with lifting (e.g. lifting of young children). It can be tested using the Finkelstein's test

- Place the thumb of the affecting hand across the palm
- Grip the other fingers over it
- Move the hand into ulnar deviation
- Pain is aggravated by this movement

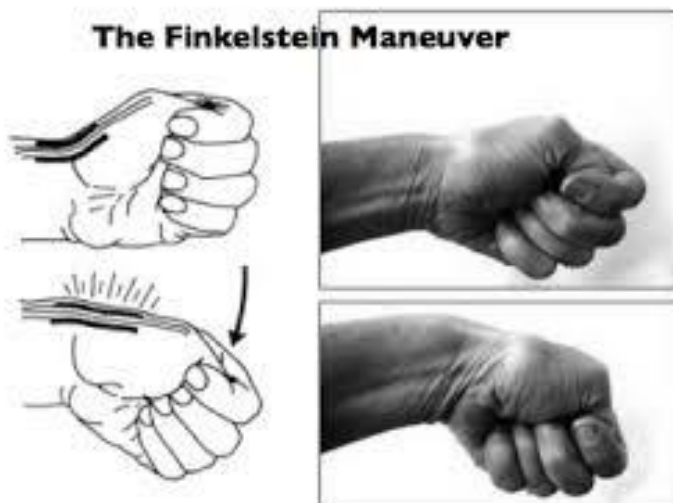

Figure 80 Finkelstein test

Treatment

Orthodoxy suggests local steroid injection, ice, NSAI and maybe surgery.

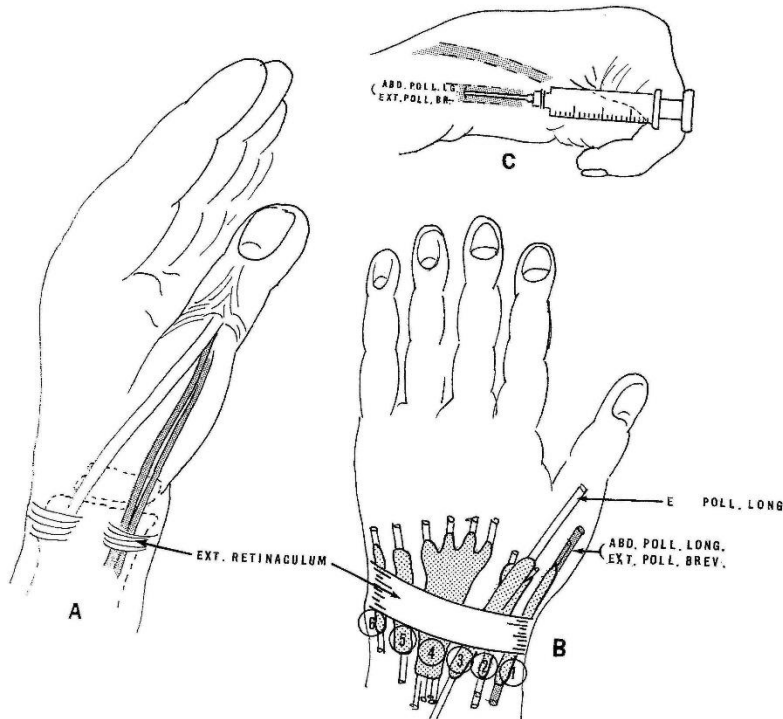


Figure 81 De Quervain's anatomy and treatment

Here, again, a change of or variation in activity is suggested, with attention being given to tension patterns in the shoulder and neck. Massage of all local and proximal tissues is useful, along with ultrasound and homeopathic remedies (rhus tox and/or ruta)

Rheumatoid Arthritis

Rheumatoid arthritis is a systemic disease that can affect almost any organ system, but is most commonly manifested as arthritis. This condition can be most disabling in the wrist and hands.

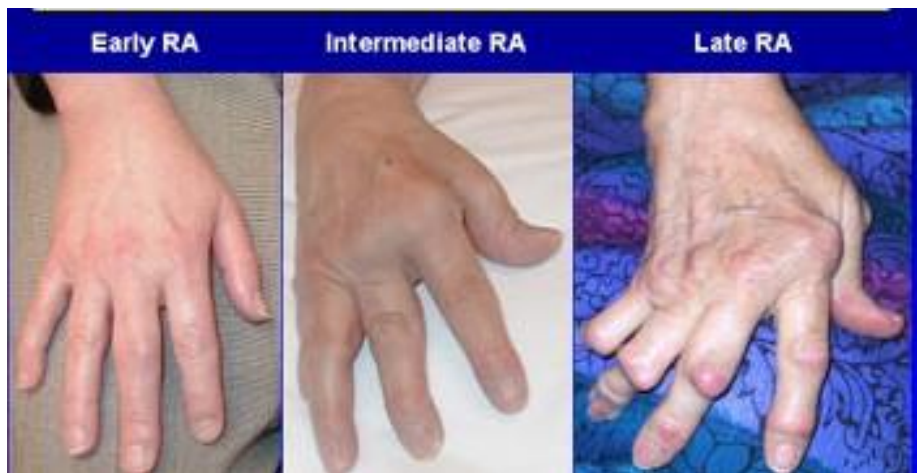

Figure 82 Rheumatoid arthritis – stages

Causes

Don't know. It has been classified as a so-called collagen vascular disease and is also thought to be autoimmune in nature. Here though, as with all autoimmune diseases, there is no definitive explanation as to why the body 'decides' to fail to recognise itself. There are blood tests (for rheumatoid factor, or inflammatory cytokines) but are indicative and not diagnostic.

Symptoms

It frequently starts between 30-40 years of age. It is often insidious in onset, with a feeling of stiffness in the hands, it being worse in the morning. Later there is an aching pain, swelling, redness and tenderness of the joints, particularly the fingers. Movement becomes limited and wasting of the adjacent muscles (the intrinsic muscles) causes the joint swellings to become apparent and the bones spindle shaped. In some cases, though, the onset can be sudden with joint pain, fever and malaise.

Typically, it affects the small joints of the hands and tends to be symmetrical (bilateral). With the pain, there will be tension of **all** the muscles of the wrist and hand and the 'stronger' ones will win, in that there will be deformation towards the ulnar side; ulnar deviation. This deviation will not be apparent in the wrist, but significantly so in the M/P joints of the fingers. There even can be a 'swan neck deformity' of the fingers; a backwards bending of the proximal interphalangeal joint, from chronic tension of the flexor and extensor tendons.

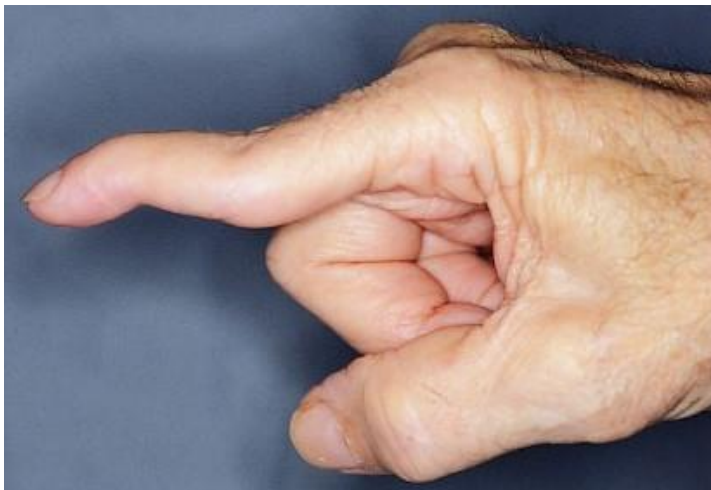

Figure 83 Swan neck deformity of fingers

Treatment

This is a difficult condition to treat, as it is a failure of the self-recognition of the immune system. Orthodox medicine treats it with

- NSAI
- Occasionally steroids (usually in short courses)
- External splinting of the joints (as it hurts to move them)
- Gold injections
- Drugs that affect metabolism (methotrexate, penicillamine)

The patient goes through active and remission phases and the joints can only be treated whilst in the passive phase, else it would be too painful.

General massage and mobilisation is appropriate to help maintain 'full function'. Diet can be considered for allergies/intolerances and one theory claims that the person have a certain bacterial colony in the gut, **proteus**, which thrives on a carbohydrate rich diet. 70% of the body's immune system functions in the gut. The theory is that the immune system produces antibodies against these, with these unintentionally acting against the body's own tissues. A diet poor in carbohydrates may be of benefit, as could administration of probiotics.

Osteoarthritis

Osteoarthritis is always classified as degenerative, or 'wear and tear', even though there is no 'afterwards therefore because of' causative factors. In the hands it affects only certain joints:

- The carpometacarpal joint at the base of the thumb
- The metacarpophalangeal joint of the thumb
- The proximal and distal interphalangeal joints of the fingers

Symptoms

There is pain swelling and joint deformity, with the deformity manifesting as a nodular deformation

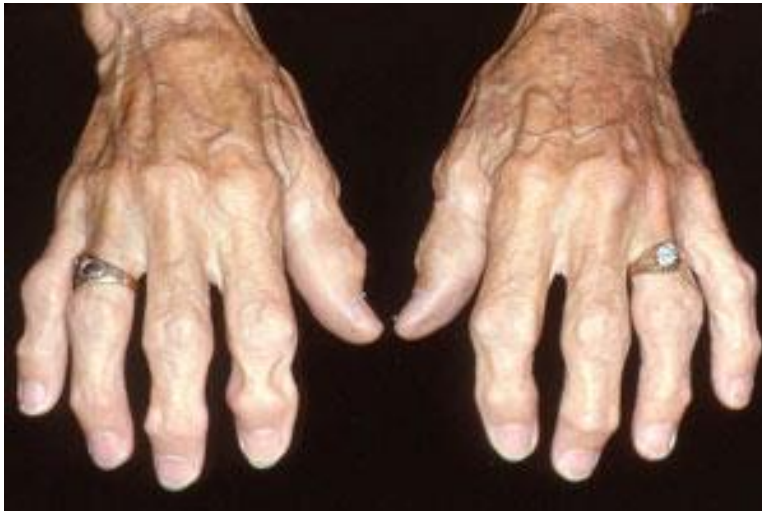

Figure 84 Osteoarthritis of the hands

- Proximal interphalangeal joint – **Bouchard's nodes**
- Distal interphalangeal joint – **Heberden's nodes**

Treatment

Keeping the joint moving is important, as only movement will feed the articular joint surfaces; but wisdom should be used here. Diet supplements are important

- Glucosamine provides the basic building blocks of cartilage synthesis in the body and help the body with cartilage rebuilding
- Chondroitin can help reduce wear and tear in the articular cartilage by inhibiting the 'cartilage chewing enzymes'
- MSM – methyl sulphonyl methane – an organic source of sulphur; an essential element in protein synthesis
- CMO – cerosomal-cis-9-cetylmyristoleate – a substance found over 25 years ago by a scientist, who found it could stop arthritis. It needed a healthy liver for it to function (strict diet for 2 weeks, 2 weeks during treatment and 2 weeks after. No alcohol, steroids, potatoes, aubergines, bread and preferably a liver detox (like milk thistle) beforehand.

Boxer's Fracture

A boxer's fracture is a fracture to the distal end of a metacarpal

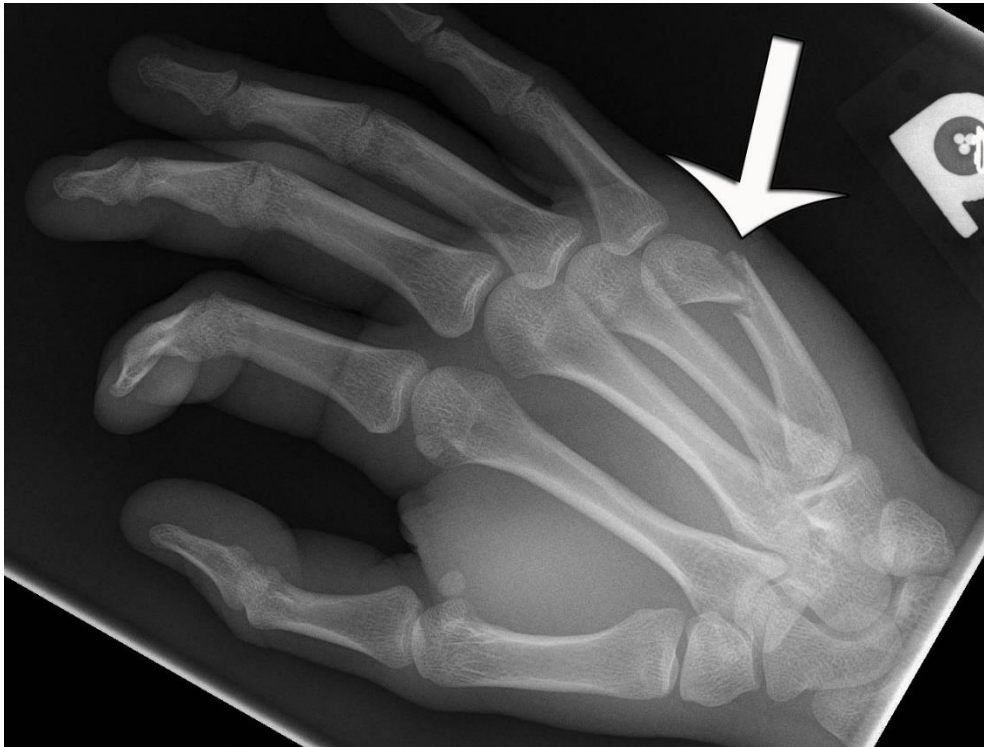

Figure 85 Boxer's fracture

Here the patient may just complain of the shape of their hand, even before the pain. On examination, the hand will 'look wrong', as the line of the knuckles may not be in a straight line; one appearing deep. This may indicate a fracture just proximal to the metacarpophalangeal joint, as seen in the X-ray.

Causes

The patient may admit to an altercation; a fight when the opponent didn't take it on the chin, as such and ducked resulting in the person being hit on the skull. It may even have occurred a couple of weeks before. There was pain and swelling then, but not now.

(Try this: press the back of one of your knuckles towards your palmar aspect. A groove will appear along the dorsal aspect of the hand. With this fracture, the knuckle will seem deep, as if being pushed) but there will be no groove.)

Treatment

Ideally the fracture should be reduced and fixed, else it will predispose to either degenerative conditions, or undue compression effects on the flexor tendons.

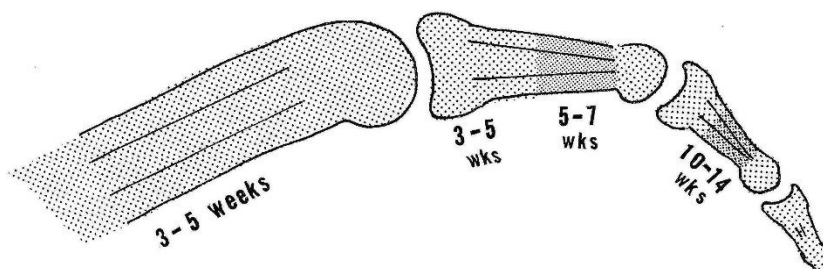


Figure 86 Fracture healing times of fingers

Avulsion fractures

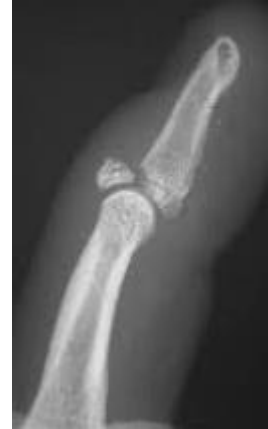An avulsion fracture occurs when there is a forced contraction of a muscles against a fixed origin, causing a piece of bone to be pulled off at the point of attachment of the tendon.

Mallet finger

A mallet finger is a flexion deformity resulting from an avulsion of the tendon of extensor digitorum.



Figure 87 Mallet finger



Mallet finger results from a forced hyperflexion at the distal interphalangeal joint, avulsing the tendon attached there.

Symptoms

There will be pain, swelling and an inability to extend the terminal phalanx

Treatment

It can be remedied by surgery to reattach the fragment via a small screw

Gamekeeper's thumb

Gamekeeper's thumb (also known as skier's thumb or UCL tear) is a type of injury to the ulnar collateral ligament (UCL) of the thumb. The UCL is torn at (or in some cases even avulsed from) its insertion site into the proximal phalanx of the thumb in the vast majority (approximately 90%) of cases.

This condition is commonly observed among gamekeepers and Scottish fowl hunters, as well as athletes (such as volleyball players). It also occurs among ordinary people who sustain a fall onto an outstretched hand.

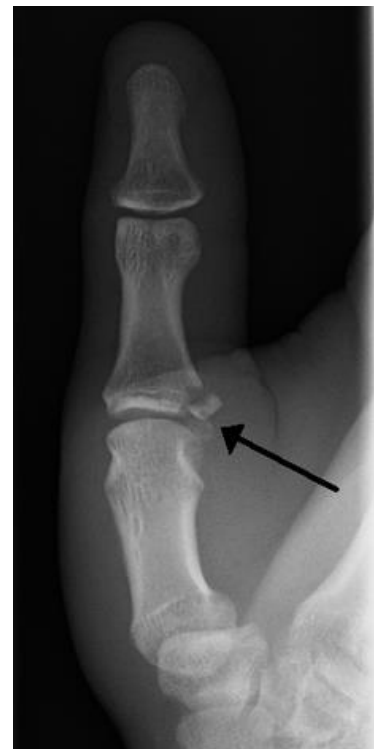

Figure 88 Gamekeeper's thumb

Dislocations

Dislocations can be obvious when they present. However, it is important that the region has sufficient external support and avoids aggravating activities for the duration of its reduction and healing.

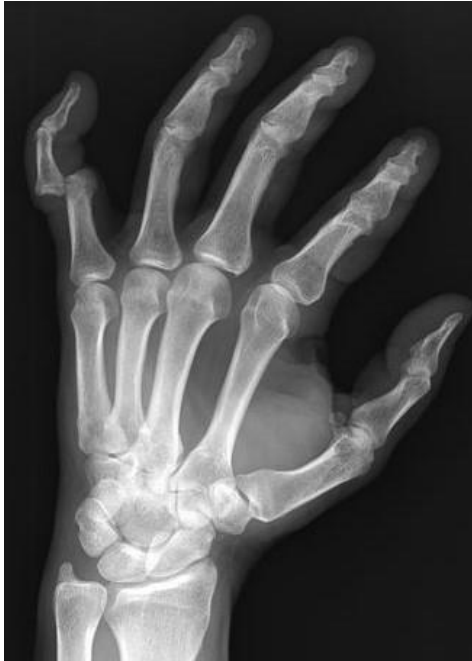

Figure 89 Finger dislocation

They usually require X-ray to confirm its presence and there are no associated fractures that also require reduction and fixation.

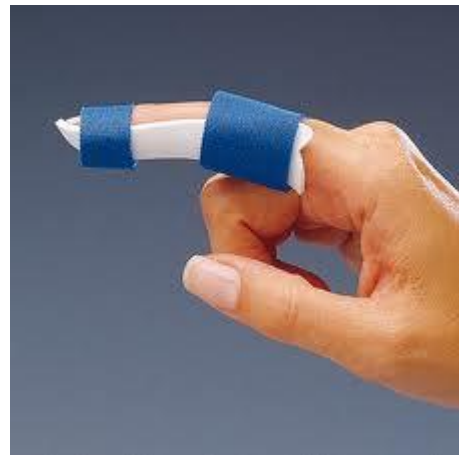

Figure 90 Finger dislocation splint

Nodules on Tendons – Trigger Finger

Nodules on flexor tendons in the fingers can cause trigger finger

Trigger Finger

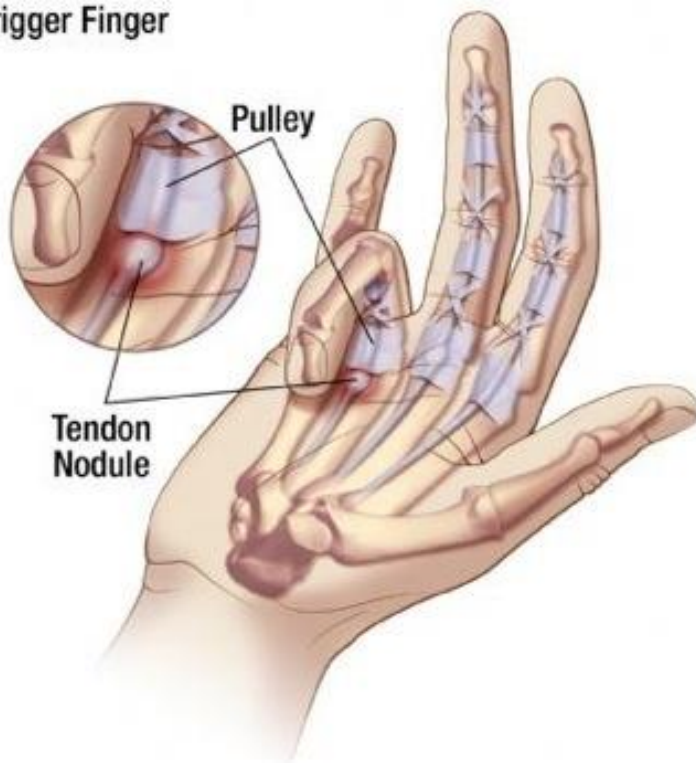


Figure 91 Trigger finger

These occur from repetitive, compressive, traumata on the tendon course, e.g. sculptor holding a mallet.

This can cause a nodular swelling on the course of the tendon, usually in the region of the metacarpophalangeal joint, where there is an increased curvature towards the palmar side of the hand. Hence the tendons there are persistently being squashed against the metacarpal joint surface.

This nodular swelling grows to such an extent that the

nodule cannot easily pass through the beginning of the tendinous sheath at the beginning of the fingers. It can begin, noticeably, as a 'clunk' feeling as the nodule initially jams, then springs through, the beginning of the tendon sheath. As the condition progresses, the nodule can grow to a size when it cannot pass through the sheath at all, so the finger remains permanently flexed.

Treatment

This condition has an insidious origin and progression. It equally can have a slow resolution. Local friction and ultrasound can help, as can steroid injections or even surgery. However, as the problems can be occupational, complete resolution can be difficult. Some sort of padding, even cycling gloves, can cushion the trauma site, reducing the repetitive impact injury.

Dupuytren's contracture

Dupuytren's contracture is a flexion deformity of the ring and/or little fingers. It occurs mainly in middle aged people of 40-60 years of age, more in males than females. It develops slowly, even over years. Knots of tissue form under the skin eventually form a thick cord that pulls the fingers into a bent position.

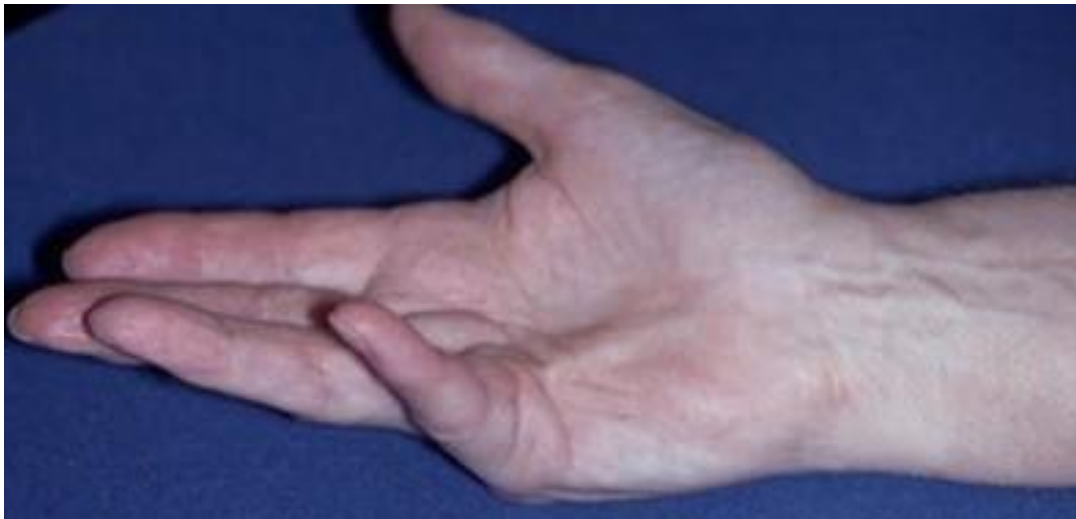

Figure 92 Dupuytren's contracture

The contractures are chronic and inelastic and are usually remedied via surgery

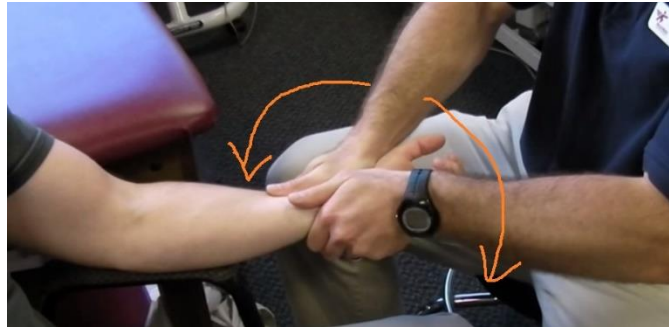Manipulations and mobilisations of Wrist

General mobilisations

Biscuit Breaking mobilisation (for carpal tunnel)

1. Position hand palm up
2. Hold hand with fingers pointing towards you
3. Place thumbs at thenar and hypothenar eminences; at either end of flexor retinaculum, though your thenar and hypothenar eminences can be used
4. Place fingers on dorsal aspect of wrist
5. Stretch across flexor retinaculum, towards each side, levering around fingers, as breaking a biscuit
 - a. This is a non-physiological movement to help stretch the flexor retinaculum and mobilise the carpal bones

Figure 93 Biscuit breaking



Torsion

1. Hold the hand with the fingers pointing towards you
2. Hold wrist with thumbs/thenar eminences on one side and index fingers on other
3. One hand pulls one side wrist into flexion; other hand pushing it into extension
4. Rhythmically alternate this movement
5. Can be repeated with wrist supine or prone
 - a. Non-physiological movement for mobilisation

Figure 94 Torsion

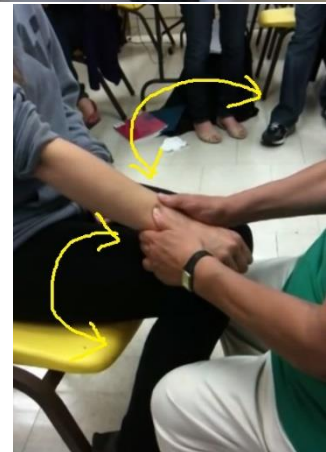

Figure of eight

1. Locate lunate (e.g.)
2. Cross thumbs over dorsal aspect of wrist, with index fingers on palmar aspect of bone
3. Hold rest of their hand with yours
4. Transcribe a 'figure of 8' in both transverse and/or vertical plane

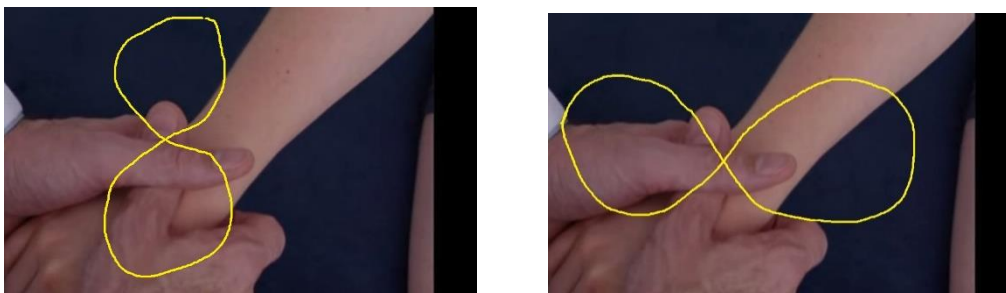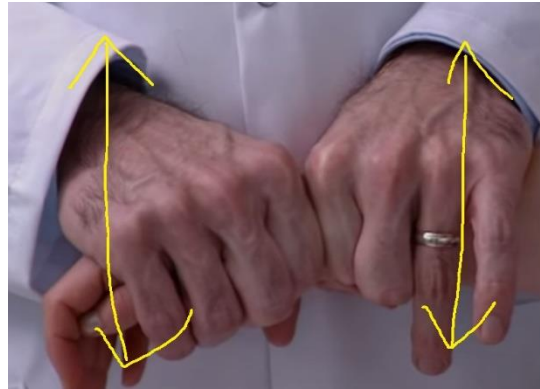


Figure 95 Figure of 8

Shearing of radio carpal

1. Locate radiocarpal joint line
2. Position hands either side of this
3. Grip (not too) firmly
4. Shear wrist anterior and posterior

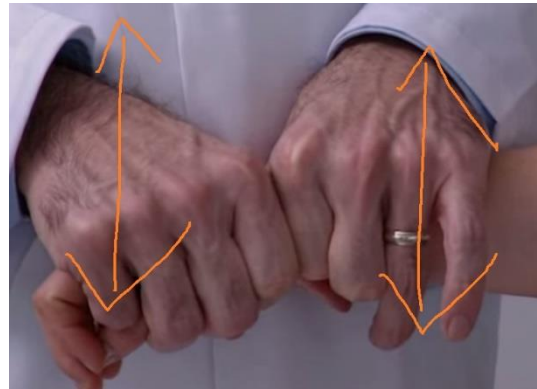
Figure 96 Shearing radiocarpal



Shearing of intercarpal joint

1. Hold hand with your little finger is hooked in the web of thumb
2. Grip
3. Shear wrist anterior and posterior

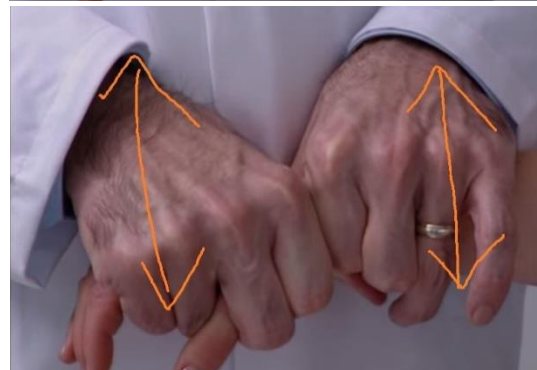
Figure 97 Shearing intercarpals



Shearing of carpometacarpal joints

1. Move hand with little and ring finger hooked in web of thumb
2. Grip
3. Shear wrist anterior and posterior

Figure 98 Shearing carpometacarpal joints



Manipulation of wrist joints

1. Fix on a bone (e.g. lunate) with the figure of 8 technique
2. Pull to create a mild traction through the wrist
3. Move the wrist rhythmically into flexion/extension
4. Manipulate the bones/joints via a momentum induced thrust (MIT) [whiplash] by sharply moving the wrist into partial extension and pushing the lunate anterior
5. This can be used for all the carpal bones, except the pisiform

Figure 99 manipulation of wrist

